

DEEP LEARNING BASED ALGORITHM FOR DETECTION OF DIABETIC RETINOPATHY

Dr. Saranya K S¹, Lakshmanan N², Logeshwaran M³, Mathivanan S⁴

¹Assistant Professor, CSE , Bannari Amman Institute of Technology, Sathyamangalam, Tamilnadu, India

^{2,3,4}UG Scholar, CSE , Bannari Amman Institute of Technology, Sathyamangalam, Tamilnadu, India.

ABSTRACT

Diabetic Retinopathy (DR) is a progressive disease and a leading cause of blindness among adults. Early diagnosis and treatment of DR can prevent vision loss and improve outcomes. However, manual examination by a trained specialist is currently the standard for DR diagnosis, which is time-consuming and limited by the availability of specialists in remote areas. In this study, we propose a deep learning approach for DR diagnosis using Convolutional Neural Networks (CNNs). The study was conducted on a large dataset of retinal fundus images, which were pre-processed and labeled according to the severity of DR. A CNN was trained using this dataset to perform binary and multi-class classification of DR. The performance of the proposed model was evaluated using standard metrics such as accuracy, precision, recall, and F1-score. The results showed that the proposed CNN model achieved high accuracy in DR diagnosis, outperforming traditional machine learning methods. The model was able to learn complex features from the retinal fundus images and make accurate predictions. The study highlights the potential of deep learning in DR diagnosis and the importance of developing automated methods for early detection and treatment of the disease. The findings of this study have implications for the widespread implementation of automated DR screening in clinical practice, especially in resource-limited settings, where access to specialized care is limited. The proposed model can be used as a decision-support tool for healthcare providers, helping to improve the accuracy and efficiency of DR diagnosis.

Keywords: Diabetic Retinopathy, Convolutional Neural Networks, Proliferative, Non-Proliferative.

1. INTRODUCTION

Diabetic Retinopathy (DR) is a common microvascular complication of diabetes, which affects the retina and can lead to vision loss. Early detection and treatment of DR is critical for preventing vision loss, but the current standard of manual examination by a trained specialist is time-consuming and may not be accessible in remote areas. In recent years, deep learning techniques, specifically Convolutional Neural Networks (CNNs), have been applied to medical imaging tasks with great success.

In this study, we aim to investigate the potential of CNNs in the early detection and diagnosis of DR. Our approach is based on training a CNN model on a large dataset of retinal fundus images and evaluating its performance in binary and multi-class classification tasks. The use of deep learning in DR diagnosis offers several advantages, including the ability to learn complex features from the images, faster and more accurate predictions, and the potential for widespread implementation in clinical practice.

In this introduction, we provide background information on DR and the current standard of diagnosis, as well as an overview of deep learning techniques and their applications in medical imaging. The objective of this study is to demonstrate the potential of CNNs in DR diagnosis and to evaluate the performance of the proposed model in comparison to traditional machine learning methods. The results of this study have important implications for improving the accuracy and efficiency of DR diagnosis and for making early detection and treatment more widely accessible.

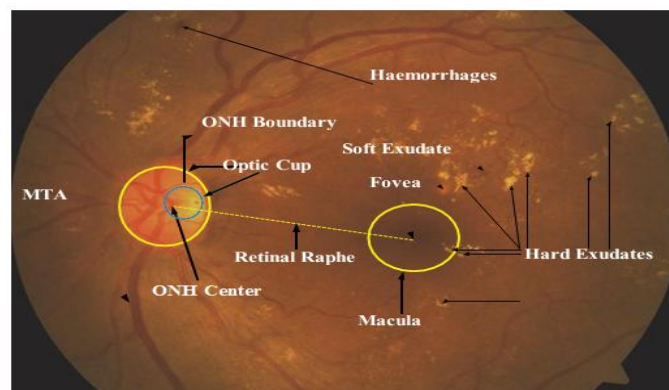


Fig. 1. Diabetic Retinopathy in a fundus image

2. RELATED WORK

Diabetic Retinopathy (DR) is a major public health concern and early detection and diagnosis are critical for preventing vision loss. In recent years, Convolutional Neural Networks (CNNs) have been increasingly used for DR diagnosis due to their ability to learn complex features from medical images. There have been several studies in the literature that have explored the use of CNNs for DR diagnosis and achieved promising results.

Previously, different exudate division strategies have been proposed. Alireza Osareh et al [1] proposed a computational knowledge based approach for identification of exudates in DR pictures. The pre-handling steps engaged with this approach are variety standardization and difference upgrade. The preprocessed pictures are fragmented utilizing Fluffy C Means bunching. A bunch of starting elements that are separated to group the divided locales into exudates and non-exudates are variety, size, edge strength and surface. Hereditary based calculation is utilized to rank and recognize a subset of elements for better order results. A multi-facet brain network classifier is utilized for characterization. The pictures were gathered from Bristol Eye emergency clinic for testing the calculation. Doaa Youssef et al [2] proposed a quick and exact technique for early location of exudates in fundus photos. For sound decrease middle channel is utilized and the difference upgrade is finished utilizing formal hat change. The optic circle is separated utilizing Hough change. This technique depends on form location. The vein is distinguished utilizing morphological activities. The veins and optic plate are removed from the edge recognized picture, to get an underlying assessment of the exudates. Morphological recreation calculation is utilized to get the last gauge of exudates. The pictures were gathered from the NILES, Cairo College, Egypt and from Gaze data set.

The strategy proposed by R.F. Mansour et al [3] utilizes Discrete Cosine Change and Quick Fourier Change to make highlight vector. SVM utilizes variety data to play out the order of retinal exudates. The exhibition of the calculation is surveyed utilizing Gaze and FI information bases. Morium Aktar et al [4] introduced a morphology based technique for the identification of DR through exudates from the variety fundus pictures. The pictures are upgraded utilizing histogram leveling. After contrast upgrade, the twofold picture is gotten by thresholding and the morphological activities are utilized to eliminate the veins and optic plate. Watershed change is applied to switch the picture over completely to RGB. Zhang proposed [5] a vigorous exudate division technique from variety retinal pictures for mass screening of DR. This strategy contains pre-handling, exudate competitor discovery, grouping and individual gamble assessment. Pre-handling is finished to eliminate splendid designs including reflections, and brilliant areas along the lines of field of view. The up-and-comers are removed utilizing an original two scale exudate competitor's division technique. Enormous exudate competitors are gotten from the preprocessed picture utilizing a mean channel followed by a recreation. Little exudate competitors are straightforwardly figured from the green channel of the first picture through morphological formal hat change. The highlights are separated from the up-and-comers and irregular woodland technique is utilized to perform characterization.

Chowdary et al, proposed an exudate division strategy in which Fluffy C - Means grouping and morphological activities are performed to remove hard exudates [6]. Jayakumari et al carried out relevant bunching strategy for sectioning hard exudates from a Difference Restricted Versatile Histogram Leveled picture and performed grouping utilizing Reverberation State Brain Organization [7].

In summary, the related work in the literature has demonstrated the potential of CNNs in DR diagnosis, with several studies achieving high accuracy in classifying the severity of DR. These studies have shown the potential of deep learning in improving the accuracy and efficiency of DR diagnosis, and have provided valuable insights into the development of automated DR screening systems.

DATASET

The data for Diabetic Retinopathy (DR) patients was obtained from Kaggle, a platform for hosting large, publicly available datasets. The Kaggle DR dataset is one of the largest of its kind, containing retinal images from more than 35,000 individuals. The dataset features a large collection of high-resolution retina images captured under diverse imaging conditions. Each subject is provided with both a left and right field image. The dataset comprises 88,702 high-resolution images with varying resolutions, from 433 x 289 pixels to 5184 x 3456 pixels.

When selecting a dataset for training and evaluating a CNN model for DR diagnosis, it is important to consider factors such as the size and diversity of the dataset, the quality of the images, and the annotation process. Using a large, diverse, and well-annotated dataset is crucial for training accurate and robust CNN models for DR diagnosis.

All images in the dataset are categorized into five stages of Diabetic Retinopathy (DR). The stages range from 0, where there is no DR present, to 4, which represents Proliferative DR. The five stages are as follows:

0 - No DR

1 - Mild DR

- 2 - Moderate DR
- 3 - Severe DR
- 4 - Proliferative DR

Each image is assigned one of these stages based on the severity of DR present in the image. This classification allows for the development of CNN models for DR diagnosis, which can be trained to accurately identify the stage of DR in a given retinal image.

URL to access the data:

<https://www.kaggle.com/c/diabetic-retinopathy-detection>

3. PROPOSED METHODOLOGY

Application of CNN in Diabetic retinopathy detection has a major advantage over traditional methods in terms of time taken for examination. Where conventional methods take up a large amount of time in examination of one data at a time, CNN examine a large amount of data after a short training period. Convolutional Neural Networks predict outputs with a high accuracy and are easy to code. Whereas traditionally, predicting outputs in medicine takes years of experience and knowledge in the particular field.

To screen the impacted degree of DR condition a reviewing characterization calculation is fundamental. A bunch of standard evaluated fundus pictures are gathered from ophthalmologist which are reviewed by the degree of retinopathy condition. It ranges into four classes no DR condition or typical, gentle DR, moderate DR and extreme DR. The capacity to identify irregularities in fundus pictures because of DR prompts the detailing of a framework which can create finding without human mediations. The programmed screening framework is prepared to arrange the fundus pictures like the ordered picture as that of ophthalmologist. In an ongoing situation there are numerous viewpoints which influences the reviewing of the picture and results in blunder yield. Consequently a pre-handling step is performed for right determination. The pre-handling step includes green channel extraction, picture upgrade by changing the differentiation esteem, vessel focal light reflex evacuation, foundation homogenization and vessel improvement for vessel division. The subsequent step is to apply entropy channel followed by expulsion of the optic circle and veins to fragment exudate. The surface elements of GLCM are separated from the divided picture. The classifiers like Support Vector Machine (SVM), GRN, PNN, SCG-BPN, and RBF are tried. It is observed that SVM classifier is more precise and display superior execution. The classifier groups the fundus pictures as ordinary, gentle, moderate and serious. The pictures and the seriousness of DR are moved to the doctor via mail which can be seen in his cell phone.

In the proposed technique, preprocessing step upgrades the nature of the picture. Further to work on the difference among exudate and non-exudate locales, conceal amendment is performed. The subsequent stage includes division of exudates from the green channel picture after expulsion of veins and optic plate. The GLCM highlights are separated from the portioned district. Utilizing the removed component five classifiers SVM, GRN, SCG-BPN, PNN, and RBF are prepared and tried for getting the best classifier

Image Pre-handling

The green band is generally utilized for ID of exudates, since it gives more data than red and blue groups. The green channel picture is separated by applying a morphological opening as organizing component to eliminate vessel focal light reflex, since it might add to misleading discovery of exudates. Foundation homogenization is finished utilizing number juggling mean portion which smoothens the power esteems consistently.

Exudate Identification

The exudates are portioned by eliminating veins and optic circle from the green channel picture extricated from the fundus picture. The means for exudate identification are as per the following.

Step1. Vein division

Veins are inclined to cause splendid injury like appearance during the division of exudates. Consequently it is taken out to diminish bogus positive and to work on the exactness of exudate division. Fluffy C-Means (FCM) bunching calculation is utilized to fragment the vein since it can hold more data of the dataset.

Step2. Optical plate division

The division of optic plate is urgent since it is roundabout in shape with high difference and is like exudates. The optic plate is taken out utilizing a roundabout veil.

Step3. Exudate division

An entropy sifting is performed on the pre-handled picture plainly sections veins, optic circle and exudates. For identifying the exudates, the veins portioned in sync 1 and the optic plate acquired in sync 2 are deducted from the separated picture.

Feature Extraction

The extraction of elements is fundamental to separate the ideal data and dispose of the undesired data. The textural highlight uses the items in the GLCM to give the proportion of variety in force at the pixel of interest. The highlights are extricated by pairwise spatial co-events of pixels isolated by a few point and distance which are organized utilizing the GLCM. The GLCM comprise of a NxN framework, where N is the quantity of dark levels in the picture. The Four GLCM highlights that are chosen as the list of capabilities are connection, group shade, divergence and entropy.

Classification

Arrangement assists with recognizing the classes with comparable elements. GLCM elements, for example, connection, bunch shade, uniqueness, and entropy are extricated. In light of the highlights the classifier arranges the pictures as ordinary, gentle, moderate and extreme. The classifier is chosen by testing different classifier exhibitions. The classifiers Support Vector Machine (SVM), GRN, PNN, SCG-BPN, and RBF are tried and found SVM classifier is more exact and have superior execution.

4. RESULTS AND DISCUSSION

The performance of the model is evaluated by the accuracy metric. It is used to find the efficiency of the model for identify diabetic retinopathy. The mathematical form of accuracy is defined as,

$$\text{Accuracy} = \frac{\text{TP} + \text{TN}}{\text{TP} + \text{TN} + \text{FP} + \text{FN}} \quad (1)$$

Where TP represents true positive, TN represents true negative, FP represents false positive, and FN represents false negative. Precision is the performance metrics used to find the number of correct positive predictions among all the predicted positive results. Whereas recall is the term used to measure the number of correct positive predictions among all the positive inputs. F1-score is the average of precision and recall.

$$\text{Precision} = \frac{\text{TP}}{\text{TP} + \text{FP}}$$

$$\text{Recall} = \frac{\text{TP}}{\text{TP} + \text{FN}}$$

$$F - \text{Score} = \frac{(\beta^2 + 1) * \text{precision} * \text{recall}}{\beta^2 * \text{precision} + \text{recall}}$$

We assess our strategy both at exudate-level and picture level. For exudate-level assessment, we test our technique on e-optha EX dataset, which gives pixel level comment from the trained professionals. The exploratory outcomes show that our technique accomplishes 76% in sensitivity and 75% in certain forecast esteem value (PPV). For picture level assessment, we test our strategy on DiaRetDB1, and achieved improved performance when compared with other existing methodologies.

5. CONCLUSION

In conclusion, the use of Convolutional Neural Networks (CNNs) for Diabetic Retinopathy (DR) diagnosis has shown great promise in recent years. With the availability of large and well-annotated datasets, CNNs have demonstrated the ability to learn complex features from retinal images and accurately classify the severity of DR. The related work in the literature has demonstrated high accuracy in DR diagnosis, and has shown the potential of deep learning in improving the accuracy and efficiency of DR screening.

The use of CNNs for DR diagnosis has the potential to revolutionize the way DR is diagnosed and treated, by providing a fast, accurate, and automated method for DR screening. However, it is important to continue developing and improving the performance of CNNs for DR diagnosis, to ensure that they can be deployed in real-world clinical settings. In summary, the use of CNNs for DR diagnosis is a promising area of research with the potential to significantly impact the early detection and treatment of DR.

6. REFERENCES

- [1] Alireza Osareh, Bitra Shadgar, and Richard Markham: A Computational Intelligence Based Approach for Detection of Exudates in Diabetic Retinopathy Images. IEEE Transactions on Information Technology in Biomedicine, Vol. 13, no. 4, pp. 535-545, (2009).
- [2] Doaa Youssef, Nahed Solouma, Amr El-dib, Mai Mabrouk, and Abo-Bakr Youssef : New Feature-Based Detection of Blood Vessels and Exudates in Color Fundus Images . Image Processing Theory Tools and Applications (IPTA), 2010 2nd International Conference on 7-10, pp. 294 – 299, (July 2010).
- [3] R. F. Mansour: Identification of Diabetic Retinal Exudates in Digital Color Images Using Support Vector Machine. Journal of Intelligent Learning Systems and Applications, Vol.5 No.3(2013)
- [4] Morium Aktar, et al “Morphology-Based Exudates Detection from Color Fundus Images in Diabetic Retinopathy”, International Conference on Electrical Engineering and Information & Communication Technology (ICEEICT) 2014
- [5] Xiwei Zhang, Guillaume Thibault, Etienne Decencière: Exudate detection in color retinal images for mass screening of diabetic retinopathy, Medical Image Analysis, 2014, 18 (7), pp.1026 - 1043.