

## ADVANSYNC FIXED FUNCTIONAL APPLIANCE: A REVIEW

Deepak M. Soni<sup>1</sup>, Rajeev Sharma<sup>2</sup>

<sup>1</sup>MDS Orthodontics, CHC Kuthera, Directorate Of Dental Health, Shimla, Health and Family Welfare Department, Himachal Pradesh, India.

<sup>2</sup>MDS Orthodontics, PHC Sammerkot, Directorate Of Dental Health, Shimla, Health and Family Welfare Department, Himachal Pradesh, India.

### ABSTRACT

Class II malocclusions are the most prevalent skeletal disharmony encountered in all age groups accounting for nearly 15-20 % of the work of orthodontics. Numerous ways to treat Class II malocclusions include removable and fixed functional appliances, elastics, extractions, headgear, implants, non-implant supported distalizers and even surgery. Orthodontists are creating newer fixed Class II correcting appliances to limit reliance on patient compliance that, if lacking can lead to longer treatment times and less than ideal treatment outcomes. There are many different compliance free inter-arch appliances including the Herbst, Mandibular Anterior Repositioning Appliance (MARA), and Advan Sync among others. Advansync, the latest addition in this modality consists of crowns cemented to the maxillary and mandibular permanent first molars, which are connected by telescopic rods. The telescopic mechanism acts constantly to posture the mandible forward upon closure, with the goal of enhancing mandibular growth to correct the Class II malocclusion. Understanding the specific skeletal and dental effects of each appliance is vital to proper appliance selection based on individual patient requirements. Therefore, the purpose of this article is to elaborate the skeletal and dentoalveolar effects of the AdvanSync appliance in the correction of Class II malocclusions in growing patients.

**Keywords :** Class II Malocclusion , Fixed Functional Appliances , Advansync Appliance.

### 1. INTRODUCTION

Class II malocclusions represent a disproportionate relationship where the lower teeth are located farther posteriorly than the upper either due to skeletal factors, dental factors, or a combination of both. When evaluating treatment options for Class II patients, the extent of the skeletal discrepancy and the skeletal maturity of the patient need to be considered. Treatment modalities to correct Class II malocclusions include camouflage with selective extraction patterns, orthopedic forces delivered with headgear, growth modification with jaw Orthopedics using functional appliances in growing patients as an intermediate treatment option , removable and fixed intra arch and interarch appliances as well as orthognathic surgery to reposition jaw or both jaws.<sup>1</sup> Earlier methods for treatment of Class II patients typically involved removable compliance based removable functional appliances e.g. Activator, Bionator, Frankel's Functional regulator and Twin Block appliance and intermaxillary Class II elastics. Overtime, lack of patient compliance and the desire to produce more predictable results in a more efficient manner led to the development of numerous fixed appliances.

Since 1930s Class II malocclusion benefits from functional appliances. Use of fixed functional appliances also known as "noncompliant Class II correctors" is an effective way to treat Class II malocclusion in post adolescent patients where the growth is mostly completed, thus dentoalveolar changes takes place predominantly rather than skeletal changes.<sup>2</sup> They are divided into rigid, flexible, and hybrid appliances. With rigid appliances, the patients could not close in centric relation reducing the mandibular movements during the therapy stage making it quite inconvenient.<sup>3</sup> Flexible fixed functional appliances allow a greater range of mandibular movements and a good mandibular opening; but chances of breakage were more commonly observed. Hybrid appliances are a combination of rigid as well as flexible fixed functional appliances, allowing better adaptation to perform such functions like swallowing, mastication, speech and inhalation because of its small size. These appliances serve the main objective of moving the teeth by applying 24-h elastic continuous force. They generate forces that vary between 150 and 200 g. In contrast to removable appliances, which have an "intermittent" mode of action, the fixed ones work "continuously." Class II correction with a fixed functional appliance is a combination of skeletal and dentoalveolar changes, which include restraining maxillary growth, dubbed as the "headgear effect," retroclination of maxillary and proclination of mandibular incisors, distalization of upper and mesial movement of lower molars, along with clockwise rotation of the occlusal plane<sup>4</sup>.

### 2. INDICATIONS OF FIXED FUNCTIONAL APPLIANCES

1) The correction of skeletal anomaly in young developing individuals.

- a) Skeletal class II with retrognathic mandible.
  - b) Skeletal Class II with maxillary protrusion.
  - c) Skeletal class III with retrognathic maxilla.
- 2) Making use of the residual growth left in neglected post-adolescent patients who have passed the maximal pubertal growth and are too old for removable functional appliances.
- 3) In adults patients
- Anchorage in upper molars distalization to correct dental class II molar relationship.
  - Enhance anchorage in cases with extractions.
  - Used as mandibular anterior repositioning splint in patients having Temporomandibular joint disorders.
  - Post-surgical stabilization of class II / class III malocclusion.
  - Compensatory treatment of mandibular deficiency in adult patients.
4. Unilaterally for functional midline shifts.
5. Residual Class II correction after treatment with extractions.
6. Class II, Subdivision, with no extraction treatment.
7. As anchorage for space closure with mesialization of posterior teeth in cases of agenesis of mandibular second premolars or extraction of mandibular first molars.

### 3. CONTRAINDICATIONS

- ♣ Patients with periodontal issues.
- ♣ Patients with gingivitis in the mandibular anterior region.
- ♣ Patients with mandibular incisors tipped or anteriorly projected.
- ♣ Patients with marked gingival smile.
- ♣ Patients with a tendency to open bite.

### 4. MODE OF ACTION OF HYBRID FIXED FUNCTIONAL (HFF) APPLIANCES

The appliance is tooth borne and exerts its effects to the underlying bone via teeth by transmitting the forces developed as a result of the continuous forward posturing of the lower jaw. (Graber et al., 1997)<sup>5</sup> The correction consists of advancing the mandible to a forced anterior position to stimulate growth (orthopedic - 30%–40%) and harmonize skeletal defects and also by eliciting dentoalveolar effects (60%–70%). The general mode of action is one or the combination of following:

- Mandibular growth stimulation and supplementary lengthening
- Maxillary growth restriction
- Dentoalveolar changes
- Adaptive changes occur in distracted condylar head and Glenoid fossa location to more vertical and anterior position.
- Changes in neuromuscular structure and function that induce bone remodelling.

<sup>6</sup>The ensuing skeletal alterations have been attributed to morphologic adaptations to altered muscular tone and to a change in the traction direction exerted by the masticatory muscles. A myostatic reflex is produced leading to isometric contractions, which in turn stimulates the protractor muscles and inhibits the mandibular retractor muscles. According to growth relativity hypothesis, variation in the postural activity of the lateral pterygoid muscle because of the hybrid functional appliances induced increased contractile activity and the iterative activity of the retrodiscal pad, and subperiosteal ossification of the posterior border of ramus which modifies the condylar cartilage's growth rate and direction. This produces a more anterior or posterior growth rotation of the mandible, which lengthens the mandible<sup>6</sup> [Figure 1]. Petrovic et al.<sup>7</sup> showed that additional growth of the condylar cartilage was due to hyper propulsion effect of the fixed functional appliances which stimulated the prechondroblastic zone cells.

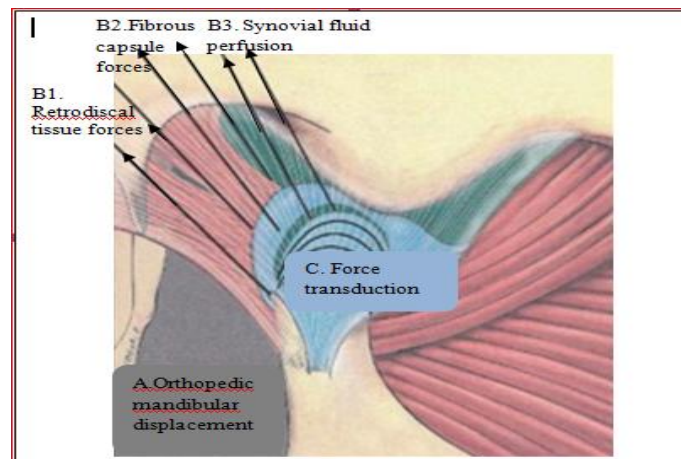


Figure 1: Growth relativity hypothesis for condylar and glenoid fossa growth with continuous orthopaedic displacement.

Of the fixed functional appliances available to the orthodontist today for the correction of Class II dentoskeletal malocclusion are Herbst Appliance<sup>8,9</sup>, mandibular protraction appliance (MPA)<sup>10</sup>, Jasper Jumper<sup>11</sup>, The mandibular anterior repositioning appliance (MARA)<sup>12</sup> and the AdvanSync2 (Ormco Co, Glendora, Calif). Other entries in list are the Calibrated force module, Eureka Spring, Sabbagh Universal spring, FORSUS-Fatigue-resistant device, The Twin Force Bite Corrector (TFBC), Alpern Class II closers, Forsus Nitinol Flat Spring, Vibhute Class II Correction Appliance (VCCA). The effects of AdvanSync appliance have not been well documented in the literature yet.

## 5. ADVANSYNC APPLIANCE

Many design variations of the Herbst appliance have been invented over past 50 years. Advansync appliance is a recent modification of the Herbst appliance, also known as Molar to Molar appliance. AdvanSync was developed by Terry and Bill Dischinger in 2008 in conjunction with Ormco<sup>TM</sup> for treating skeletal class II malocclusion.<sup>13</sup> The appliance was designed to advance the mandible to class I occlusion within 6–9 months, while allowing simultaneous use of fixed orthodontic appliances. The appliance is almost half the size of the MiniScope Herbst appliance that has been in use. Because of the smaller size, it fits more comfortably in the posterior of the mouth. The sores problem with previous Herbst appliances in the lower premolar area from the screw housings, was eliminated in this design. The small sized appliance is not apparent in the mouth like previous Herbst designs, so is more acceptable to patients. A bonus that came out of the smaller design was the ability to bracket every tooth forward of the appliance. The AdvanSync is a fixed tooth-born functional appliance consisting of crowns cemented on maxillary and mandibular permanent first molars, a position where orthopaedic forces are applied. The AdvanSync shows more headgear effect but less mandibular length enhancement.<sup>14</sup>



Figure 2: Advansync Appliance

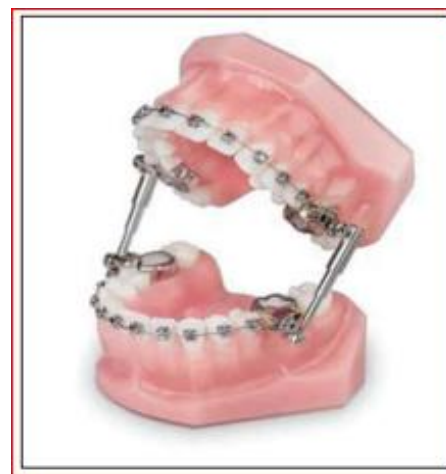

Figure 3: Parts of Advansync: Lumens are 16% larger with radiused internal edges for increased lateral movement

### 5.1 Advantages of AdvanSync

Are as follows:

#### A) Class II Treatment in Class I Time.<sup>15</sup>

- 1) Placed simultaneously with initial bonding, eliminating the need for two-phase treatment.
- 2) It gives constant activation and has no need for patient compliance.
- 3) Appliance can be given during mixed-dentition phase.

#### B) Engineered for efficient correction.<sup>15</sup>

- 1) Reinforced Spirallock threading maximizes screw engagement. [Figure 3]
- 2) Advanced metal injection molding provides a highly durable and robust appliance.
- 3) Upper and lower dual screw housing allow higher versatility throughout treatment.
- 4) Electropolished manufacturing process provides smoother operation.<sup>11</sup>

#### C) Convenient and Easy-to-Use.<sup>15</sup>

- 1) Easy to deliver for doctors and staff.
- 2) Allows freedom of movements mesial to the molar crowns.
- 3) Has built-in activation.

#### D) Improved patient comfort and satisfaction.<sup>15</sup>

- 1) Has 50% shorter arms which reduces discomfort and tissue irritation.
- 2) Sits further back in the mouth than other Herbst appliances, for a more discrete appearance.
- 3) Facilitates enhanced lateral jaw movement. [Figure 3]
- 4) Speech is unaffected— unlike removable appliances.
- 5) Design enhancements facilitate increased hygiene.<sup>15</sup>

### 5.2 Mechanism

The AdvanSync is designed to allow simultaneous fixed orthodontic appliance treatment. (0.0220 × 0.0280 ) slot edgewise bracket system is fully bonded with the brackets on the mandibular incisors having a built-in labial root torque. Bonding lower anterior brackets also prevents the side effect of mesiolingual rotation of the molars. This functional appliance includes stainless-steel crowns with single archwire tubes on permanent first molars. The AdvanSync did not include lower lingual holding arches, and the maxillary and mandibular crowns of this appliance are connected by telescopic rods. The telescopic mechanism acts to constantly posture the mandible forward upon closure, with the goal of enhancing mandibular growth. The treatment protocol includes stepwise activation as judged by the severity of the overjet. The appliances are activated 2 to 4 mm every 3 months for 6 to 12-month duration until moderate dental overcorrection is achieved. The occlusion with the AdvanSync is overcorrected to an anterior crossbite and a Class III canine relationship with the maxillary canine in an end-to-end relationship with the mandibular first premolar or in a full-tooth relationship in the more severe cases. Over-correction is desirable to counteract some relapse of mandibular anterior repositioning. General principle is to counterbalance the relapse tendency, yet finish in a Class I position. This appliance is used during skeletal growth spurt as evaluated by the improved cervical vertebral maturation method, to avail maximum benefit.

### 5.3 Time Reference

The results of the investigation by McNamara<sup>16</sup> showed that the pubertal growth spurt, in the permanent dentition, is the best time frame to achieve a more noteworthy amount of mandibular skeletal impacts and a more modest measure of dental compensation. Pubertal growth spurt<sup>17-20</sup> (CS3–CS4)<sup>21</sup> is considered as the best time for orthopedic class II correction using growth modification procedures. Baccetti et al. found in his study that the pre pubertal phase of development in presence of residual sutural action of the maxillary skeletal structures produced the ideal result in the maxilla<sup>22</sup>.

### 5.4 Selection Of Patient

Primary considerations are aetiology, age of the patient, severity of malocclusion, growth status, patient compliance etc. for the proper selection of the appliance.<sup>1,23</sup> Growing patients (MP3 stages FG and G) and CVMI stages 2, 3, and 4 of both genders with Class II division 1 malocclusion are selected. Most suitable patients for this type of modality are with skeletal class II relationship due to a deficient/ Retrognathic mandible with ANB angle greater than 5°, needing a non-extraction treatment approach, normal or decreased lower facial height (Horizontal growth pattern), as well as normal or decreased inclination of lower incisors, Minimum crowding in dental arches, Positive VTO and absence of any signs or symptoms of temporomandibular joint disorders.



### 5.5 Installing The Appliance

Patient application of AdvanSync is simple and can be performed the same day when the orthodontic appliances are bonded. upper and lower first molars are banded and the rest of the teeth are bonded by preadjusted edgewise appliances. Normally we wait for 2-4 months after bonding for placing advansync appliance in certain instances. For the younger kids, this helps them ease into treatment with less to adjust to at the start. For some patients, the lower arch is leveled first, particularly in Class II, division 2 patients. Although this postpones the Class II correction by 2–4 months, the result is that less orthodontics needs to be done after removal of the appliance, the Class II correction occurs more smoothly without vertical issues, and thus, the overall treatment time is lessened.<sup>13</sup> Levelling arch wires are placed in sequential order until reaching 0.016 stainless steel arch wires for the bite to be sufficiently opened to provide a more comfortable mandibular advancement and easier mastication for the patient. Following thing must be evaluated before attaching the arms. If the arms get oriented in a more vertical position rather than horizontal, then remove the arms and continue the leveling and aligning until the proper overbite has been established and there is an adequate overjet to advance the mandible.<sup>13</sup> Then bands are removed to place the Advansync appliance. The Advansync appliance consisted of 4 partial crowns cemented on the upper and lower permanent first molars and 2 telescopic rods that connect the upper and lower crowns together on each side via screws by using a key supplied with the appliance. Crimpable spacers are also supplied to be placed onto the rods for additional activation or midline correction. There is no need for any transpalatal (TPA) or lingual holding arch (LHA). Gandedkar<sup>24</sup> and celikoglu et al<sup>25</sup>, suggested that lower incisor proclination, which is a drawback of advansync2 appliance can be corrected by fixed appliance with labial root torque, cinch backs and heavy stabilizing wires with miniscrew anchorage.

### 5.6 The clinical steps

1. Adequate separation of molars.
2. Proper band/crown selection (Sizes of bands are 4, 5, 6 and 7 respectively)
3. Cementation of lower bands and placement of lower archwire
4. Attachment of telescopes (right and left sides respectively) in the distal casing of upper band. This has to be performed extra-orally, after which the bands are cemented and upper archwire is placed.
5. Guide the patient to get the mandible forward, to align the lower telescopic mechanism in the mesial casing and then place the screw.

### 5.7 The appliance activation protocol : -

-On the day of placement:

This gives approx 4 mm activation.

- 1st activation:

After around 6-8 weeks, the screw from the lower mesial casing is shifted to the distal casing, thus producing around 2 mm activation.

- Subsequent activations:

After 6-8 weeks to check the correction of mandibular advancement. If required, the spacers (1 or 2 mm are placed) for further activation. Spacers are needed unilaterally- to correct midline discrepancy, if any.

Multi-step advancement over single-step advancement helps to achieve better skeletal effect and soft tissue adaptation. Dental effect is minimized. Condylar adaptation is better achieved.

At each appointment, appliance breakage (if any), appliance fit, molar relation, midline shift, and occlusal disturbance are evaluated. Once the appliances are removed, edgewise fixed orthodontic treatment is continued to achieve correct anterior torque and occlusion and adequate finish.

### 5.8 The Retention Protocol After Debonding :

The cases in which AdvanSync 2 is used can be best retained using a removable retainer with an anterior inclined plane. This helps in retaining the corrected mandibular position. Removable retainer should be worn daily for a maximum duration

### 5.9 Complications:<sup>26</sup>

-Dislodgement of the bands from the molars could be encountered. The bulkiness of the molar bands can be a disadvantage which could not resist the occlusal forces resulting in dislodgement. Hence, re-cementation of the bands may have to be employed.

-Open bite appears upon installation of the appliance because of the bulkiness of the crowns which has to be corrected post functionally by settling elastics or by using bands instead of crowns.

-Some amount of spacing also occurs in the maxillary arch during the treatment which could be attributed to the arch expansion. This was however controlled using stabilising wires and cinch backs.

-Lower molars get tipped mesially.

-Buccal arch can be traumatic to gingival.

### 5.10 Effects of advansync on skeletal and dental structures:

#### 5.10.1 Skeletal effects :<sup>26</sup>

1. Advansync2 has a head gear like effect by restraining the growth of maxilla which is beneficial in maxillary prognathic cases. This can be evidenced by the decrease in the 6 to pvt measurements and a reduction in point A to PT vertical distance.
2. An anterior force to the mandible.
3. Increase in FMA angle ( $25^{\circ}$ - $28^{\circ}$ ) and lower anterior facial height (ANS-Gn –  $58^{\circ}$ - $62^{\circ}$ ) have also been evidenced.
4. A significant increase in SNB and decrease in ANB angle.
5. Significant increase in the total length of the mandible (Co-Pog).

#### 5.10.2 Dental effects<sup>13</sup>

The direction of the forces generated by the advansync2 appliance includes sagittal, intrusive, and expansive vectors.

1. The molar-to-molar attachment brings about intrusion of the molars.
2. Mild proclination of the lower incisors shown by increase in IMPA angle. However, the amount of lower incisor proclination is lesser when compared to other fixed functional appliances where the attachment is fixed to the mandibular anterior segment thereby resulting in greater proclination of the lower anteriors.
3. Reduction in U1-FH angle I indicating reduction in axial inclination of upper central incisor.
4. A very high and significant reduction in overjet.
5. The sagittal force vector produces distal movement of the upper molars and mandibular molar mesialization.
6. Additionally, an intrusive force of the maxillary posterior region and mandibular anterior region is also evidenced.
7. The push force generated by the appliance also leads to 2-3mm of expansion of the maxillary dental arch. This can be evidenced by the increase in the maxillary intercanine, inter-premolar and the inter-molar widths in patients wherein an overall arch expansion of 3-4mm occurs.

**5.11 Post functional stability:** According to Bock et al<sup>27</sup> (2015), there was a good dentoskeletal stability for Class II correction using Herbst appliance. According to Wigal et al<sup>28</sup>, overcorrection using herbst appliance during early mixed dentition resulted in a significant reduction in overjet and correction of the molar relationship and also the correction was maintained after the fixed appliance therapy. This was attributed to continuous restraint of the maxillary growth and the dentoalveolar adaptations. Since the advansync2 appliance is a miniaturised modification of the original Herbst appliance, the treatment stability can be expected to be the same.

## 6. CONCLUSION

Functional orthopedic treatment seeks to correct malocclusions and harmonize the shape of the dental arch and oro-facial functions. According to Pangrazio et al. removable or fixed functional appliances bring about sagittal and vertical skeletal changes in the jaw positions resulting in orthopaedic and orthodontic changes.<sup>29</sup> Conventional orthodontic appliances use mechanical force to alter the position of teeth into a more favorable position. However, the scope of these fixed appliances is greatly limited by certain morphological conditions which are caused due to aberrations in the developmental process or the neuromuscular capsule surrounding the orofacial skeleton. To overcome this limitation, functional appliances came into existence. Non-compliant patients can be effectively managed by fixed functional appliances. AdvanSync2 is the recently introduced fixed functional appliance. The advantage of this appliance is that there is no need to align and level the arches before its placement so that the treatment duration is drastically reduced. This with early sagittal discrepancy correction is associated with better patient motivation and oral hygiene maintenance.<sup>30</sup> Most of the fixed functional appliances result in increased proclination of lower incisors. The unique design of molar-to-molar attachments in AdvanSync2 appliance is expected to reduce lower incisor proclination since there is no attachment in the lower anterior section.

Functional appliances do not replace fixed attachments. Indeed combined use of brackets, bands and extraoral force has the potential for the best possible and most stable long term results. It is important to note that functional appliance therapy is to be generally followed by the traditional full banded techniques for optimum results; since they deal more with the gross changes in the intermaxillary relations and are not designed for precise individual tooth movement.

## 7. REFERENCES

- [1] Jayachandran S, Wiltshire WA, Hayasaki SM, and Pinheiro FHSL, "Comparison of AdvanSync and intermaxillary elastics in the correction of Class II malocclusions: A retrospective clinical study", American Journal of Orthodontics and Dentofacial Orthopedics, Dec.2016, Vol. 150, Issue 6, pp. 979-988.
- [2] Mathur S, Raghav P, Ashutosh and Preeti, "Advansync 2: A fixed functional class 2 corrector in advanced age, A case report", Heal Talk A Journal Of Clinical Dentistry. June, 2019, Vol. 11, Issue 5 , pp. 34-35.
- [3] Kharbanda OP and Chaurasia S, "Functional jaw orthopedics for class II malocclusion. Where do we stand today?" Journal of Indian Orthodontic Society, Dec. 2015, Vol. 49, Issue 5, pp. 33-41.
- [4] Chhibber A, Upadhyay M, Uribe F and Nanda R, "Mechanism of class II correction in prepubertal and postpubertal patients with Twin Force Bite Corrector", Angle Orthodontist, July 2013, Vol. 83, Issue 4, pp. 718-727.
- [5] Graber TM, Rakosi T and Petrovic AG, Dentofacial orthopedics with functional appliance. 2nd Edn., St. Louis: Mosby Ltd, 2009.
- [6] Voudouris JC and Kuftinec MM, "Improved clinical use of twin-block and herbst as a result of radiating viscoelastic tissue forces on the condyle and fossa in treatment and long-term retention: Growth relativity", American Journal of Orthodontics and Dentofacial Orthopedics, mar. 2000, Vol. 117, Issue 3, pp. 247-66.
- [7] Charlier JP, Petrovic A and Herrmann-Stutzmann J, "Effects of mandibular hyperpropulsion on the prechondroblastic zone of young rat condyle", American Journal of Orthodontics and Dentofacial Orthopedics, Jan.1969, Vol. 55, Issue 1, pp. 71-74.
- [8] Herbst E, Atlas Grundriss der Zahnärztlichen Orthopädie. Munchen, J.F. Lehmann Verlag, 1910.
- [9] Pancherz H, "Treatment of class II malocclusions by jumping the bite with the Herbst appliance. A cephalometric investigation", American Journal of Orthodontics and Dentofacial Orthopedics, Oct.1979, Vol.76, Issue 4, pp. 423-442.
- [10] Filho CM, "Mandibular protraction appliances for class II treatment", Journal of Clinical Orthodontics, My 1995, Vol. 29, Issue 5, pp.319-336.
- [11] Jasper JJ and McNamara JA, "The correction of interarch malocclusions using a fixed force module", American Journal of Orthodontics and Dentofacial Orthopedics, Dec.1995, Vol. 108, Issue 6, pp. 641-650.
- [12] Eckart E, "Introducing the MARA", Clinical Impressions, Aug. 1998, Vol. 7, Issue 3, pp. 2-5.
- [13] Dischinger BM, "Skeletal class II case presentation: utilization of the Advansync2 appliance", Asia Pacific Orthodontic Society Trends in Orthodontics, Sept. 2018, Vol.8, Issue 3 , pp. 168-174.
- [14] Al-Jewair TS, Preston CB, Moll EM and Dischinger T, "A comparison of the MARA and the AdvanSync functional appliances in the treatment of Class II malocclusion", Angle Orthodontist, Sept. 2012, Vol. 82, Issue 5, pp. 907-914.
- [15] AdvanSync™ 2 Class II molar to molar, Available from: <https://ormco.com/products/advansync/>.
- [16] McNamara JA, Hinton RJ and Hoffman DL, "Histologic analysis of temporomandibular joint adaptation to protrusive function in young adult rhesus monkeys (Macaca mulatta)", American Journal of Orthodontics and Dentofacial Orthopedics, Oct.1982, Vol. 82, Issue 4, pp. 288-298.
- [17] Ruf S and Pancherz H, "Dentoskeletal effects and facial profile changes in young adults treated with the Herbst appliance", Angle Orthodontist, June 1999, Vol. 69, Issue 3, pp. 239-246.
- [18] Ruf S and Pancherz H, "Herbst/multibracket appliance treatment of class II division 1 malocclusions in early and late adulthood. A prospective cephalometric study of consecutively treated subjects", European Journal of Orthodontics, Aug. 2006, Vol. 28, Issue 4, pp. 352-360.
- [19] Bock N and Pancherz H, "Herbst treatment of class II division 1 malocclusions in retrognathic and prognathic facial types", Angle Orthodontist, Nov. 2006, Vol.76, Issue 6, pp.930-941.
- [20] Hagg U and Pancherz H, "Dentofacial orthopaedics in relation to chronological age, growth period and skeletal development. an analysis of 72 male patients with class II division 1 malocclusion treated with the herbst appliance", European Journal of Orthodontics, Aug. 1988, Vol.10, Issue 3, pp.169-176.
- [21] Baccetti T, Franchi L and McNamara Jr JA, "An improved version of the cervical vertebral maturation (CVM) method for the assessment of mandibular growth", Angle Orthodontist, Aug. 2002, Vol.72, Issue 4, pp.316-323.
- [22] Baccetti T, Franchi L and Toth R, "Treatment timing for Twin-block therapy", American Journal of Orthodontics and Dentofacial Orthopedics, Aug. 2000, Vol.118, Issue 2, pp.159-170.

- [23] Thushar BK and Verma S, "Treatment Outcomes in the Sagittal and Vertical Dimensions with the AdvanSync2 Class II Corrector—A Case Series", Journal of Contemporary Orthodontics, Aug. 2018, Vol.2, Issue 3, pp.14-26.
- [24] Gandedkar NH, Revankar AV and Ganeshkar SV, "Correction of a severe skeletal Class II occlusion with a fixed functional appliance anchored on mini-implants: a patient report", World journal of orthodontics, Sept. 2010, Vol.11, Issue 4, pp.369-79.
- [25] Celikoglu M, Unal T, Bayram M and Candirli C, "Treatment of a skeletal Class II malocclusion using fixed functional appliance with miniplate anchorage", European journal of dentistry, Apr. 2014, Vol.8, Issue 2, pp.276-80.
- [26] Somaskandhan A, Suresh KP, Boovaraghavan S, Priya R. and Vijayalakshmi D, "Management of Skeletal Class-II Malocclusion Using Advansync 2: A Case Series", Medico-legal Update, 2020, Vol.2020, pp.2233-42.
- [27] Bock NC and Ruf S, "Dentoskeletal changes in adult Class II division 1 Herbst treatment—how much is left after the retention period?" European journal of orthodontics, Dec. 2012, Vol.34, Issue 6, pp.747-53.
- [28] Wigal TG, Dischinger T, Martin C, Razmus T, Gunel E and Ngan P, "Stability of Class II treatment with an edgewise crowned Herbst appliance in the early mixed dentition: Skeletal and dental changes", American Journal of Orthodontics and Dentofacial Orthopedics, Aug.2011, Vol.140, Issue 2, pp.210-23.
- [29] Pangrazio-Kulbersh V, Berger JL, Chermak DS, "Treatment effects of the mandibular anterior repositioning appliance on patients with Class II malocclusion, American Journal of Orthodontics and Dentofacial Orthopedics, Mar.2003, Vol.123, Issue 3, pp.286-95.
- [30] Pancherz H and Anehus-Pancherz M, "The headgear effect of the Herbst appliance: a cephalometric long-term study", American Journal of Orthodontics and Dentofacial Orthopedics, Jun.1993, Vol.130, Issue 3, pp.510-20.