
STUDY ON THE EFFECT OF HEAVY METAL POLLUTANT IN LABIO ROHITA FROM HASDEV RIVER KORBA, CHHATTISGARH

Chandra Pratap Singh¹, Dr. Namita², Dr. Devyani Sharma³

¹Research Scholar, Department of Lifescience, Shri Rawatpura Sarkar University, University, Raipur, Chhattisgarh, India.

²Assistant Professor, Department of Lifescience, Shri Rawatpura Sarkar University, University, Raipur, Chhattisgarh, India.

³Assistant Professor, Department of Lifescience, Raipur, Chhattisgarh, India.

ABSTRACT

Heavy metals are naturally occurring elements released into the environment through geological processes, but human activities such as mining, industry, and technology have escalated their presence, especially in aquatic habitats. The accumulation of heavy metals in aquatic organisms, particularly fish like the Rohu (Labio Rohita), occurs through various routes including gills, body surface, and alimentary canal. The thesis emphasizes the importance of understanding the toxic effects of heavy metals on aquatic organisms, encompassing not only lethality and mortality but also sub-lethal effects on behavior, growth, physiology, and biochemistry. Copper, an essential element, exhibits toxic effects on aquatic environments due to its oxidative properties. It can disrupt fish physiology, induce oxidative stress, and impact immune responses. The study underscores the need for comprehensive qualitative and quantitative assessments to evaluate the effects of pollutants on aquatic organisms. This involves investigating behavioral, physiological, and biochemical changes, as well as employing statistical analysis and mathematical modeling to predict and quantify these effects. The research contributes to our understanding of the complex interactions between heavy metals and aquatic organisms, shedding light on the environmental risks posed by increasing metal concentrations resulting from human activities. The histopathological changes in the fish liver, kidney and gills were observed both Cooper and Arsenic. Sub lethal concentrations (LC₅₀).

Keywords – Heavy Metals, lethal concentration, physiology, biochemical,

1. INTRODUCTION

Heavy metals in trace amount have been normal constituents of the hydrosphere since the beginning of geological era. But the concentration of heavy metals has increased with the development of industrialized societies. Rivers, ponds and lakes are very important part of human life and civilization. Pollution due to rapid growth of civilization and industrialization all over the world had posed a serious threat to mankind the main problem created due to rapid industrialization is the disposal of waste products [1]. Anthropogenic activities have resulted in large numbers of new chemicals being released into aquatic systems and these pollutants are known to harm the organisms because of their toxicity and persistence in the environment [2]. About 40 elements enter the aquatic environment as waste due to manufacturing, mining, electroplating or dumping activates and among these cadmium, copper and zinc are well known metal pollutants in the fresh water and marine environment [3]. They occur either as soluble or insoluble complexes with other compounds present in aquatic system. These pollutants tend to accumulate in organisms and undergo food chain amplification as they get transferred to different trophic levels [4]. The chemical used in agriculture and industry are finding their way into every possible corner of the globe, thus altering the qualitative and quantitative aspects of the environments [5]. All these chemicals, heavy metals have been found in alarming quantities both in urban areas and agricultural fields, especially the metals like cooper, Arsenic, chromium, mercury etc. The discharge of heavy metals as industrial and agricultural waste and sewage effluents has prompted concern in recent years over their effects on freshwater aquatic life [6].

In the pure metals are not hazardous for us but the dangerous of their soluble compounds create problems in aquatic ecosystem like metalloid organic compounds (methyl mercury and tetra ethyl lead) are highly poisonous [7]. Heavy metals have a biochemical property and tendency to bioaccumulation. The bioaccumulation properties of metals pose a serious threat to the aquatic ecosystem [8].

2. MATERIALS AND METHODS

Collection of Water Sample

Collection of water samples from four different places (Belgiri Naala, Dhengur Naala, Hasdeo downstream of Dhengur Naala and Hasdeo Downstream of Ahran River) of Hasdeo River in Korba, Chhattisgarh, India. From every spots 20 water samples were collected and total 80 water samples were used for study. Each water samples collected

from these sites in plastic bottles. Sample was transported to Department of life science, Shri Rawatpura Sarkar University, Raipur, Chhattisgarh.

Morphological Manifestation

The findings reveal significant morphological manifestations in fish exposed to heavy metal contamination. External changes include fin erosion, scale loss, color variations, and overall body deformities. Internal morphological observations indicate tissue damage, cellular changes, and potential impairment in organ function, particularly in the gills, kidney and liver.

Test Organisms and Acclimatization

Rohu (*Labeo rohita*) was used as test Organism (Fish). Fishes were collected from Hasdeo River in Korba District, Chhattisgarh (India) with the help of local fisherman, brought to laboratory without mechanical injury and Fish were disinfected in 0.1% KMnO_4 solution for five minutes to avoid dermal infection and then rinsed with fresh water and acclimatized to laboratory conditions maintained in glass aquaria for 15 days before the experiments. If the number of death exceeded 5% in any of the batch of fish during acclimatization, that particular batch was discarded.

3. PREPARATION OF TEST CHEMICALS

Preparation of Copper (Cu) Stock Solution- $\text{CuSO}_4 \cdot 5\text{H}_2\text{O}$ (99.5% purity manufactured by Thomas Bakar Chemical Mumbai) is used as test chemical for Copper toxicity to Rohu (*Labeo rohita*). Dissolved 3.92 gm. CuSO_4 in double distilled water and diluted to 1000 ml. This is 1000 ppm stock solution of Copper. In this manner we prepared 1000 ppm, stock solution of Copper.

Copper ions exerts a broad spectrum of toxicity on physiology of fishes, the non-target aquafauna, hence copper is taken as test metal for Rohu (*Labeo rohita*) in present investigation.

Preparation of Arsenic Stock Solution- $\text{Na}_2\text{H AsO}_4$ (98.5% purity manufactured by S.D. Fine Chemical Ltd., Mumbai) is used as test chemical for arsenic toxicity to Rohu (*Labeo rohita*).

Dissolved 3.46 gm of $\text{Na}_2\text{H AsO}_4 \cdot 7\text{H}_2\text{O}$ (98.5% purity) in about 100 ml. of double distilled water and diluted it to 1000 ml. with distilled water by this manner we prepared 1000 ppm of stock solution of arsenic.

Behavioral Responses- During toxicity test the altered behaviors of exposed fishes were observed carefully based on concentration-duration response [9]. The operculum movements, surfacing activity, erratic swimming, equilibrium etc. were noted for six times.

Histopathology- Histopathology of Rohu fish (*Labeo rohita*) typically involves a series of steps to prepare and examine tissue samples under a microscope. Here's an overview of the methods used for fish histopathology.

Sample Collection: Start by collecting fish specimens that are either naturally deceased or euthanized humanely to minimize stress and tissue damage. Select specific tissues or organs of interest for histopathological examination based on the research question or suspected health issues.

Tissue Fixation: Immediately after collection, the selected tissues should be fixed to preserve their cellular structure. Common fixatives for fish histopathology include 10% buffered formalin or Davidson's fixative. Submerge the tissue samples in the fixative and ensure they are completely immersed for a sufficient duration (typically 24-48 hours) depending on the tissue size.

Tissue Processing: After fixation, rinse the tissues with water to remove excess fixative.

Dehydrate the tissues by passing them through a series of increasing concentrations of alcohol (e.g., 70%, 95%, and 100% ethanol) to remove water from the tissues. Clear the tissues using a clearing agent like xylene to remove alcohol and make them transparent. Embed the dehydrated and cleared tissues in paraffin wax to provide support for thin sectioning.

Sectioning: The embedded tissues are sliced into thin sections (usually 4-6 micrometers thick) using a microtome. These sections are then mounted onto glass microscope slides.

Staining: To enhance the contrast and visualization of cellular structures, sections are stained using various histological stains. Common stains for fish histopathology include Hematoxylin and Eosin (H&E) for general tissue examination. Other specialized stains may be used for specific purposes, such as Periodic Acid-Schiff (PAS) for detecting glycogen or special stains for detecting parasites.

Microscopic Examination: Prepared slides are examined under a light microscope. analyze the tissue sections for abnormalities, lesions, cell morphology, inflammation, and other pathological changes. Photomicrographs may be taken to document findings.

4. RESULTS

Sample processing

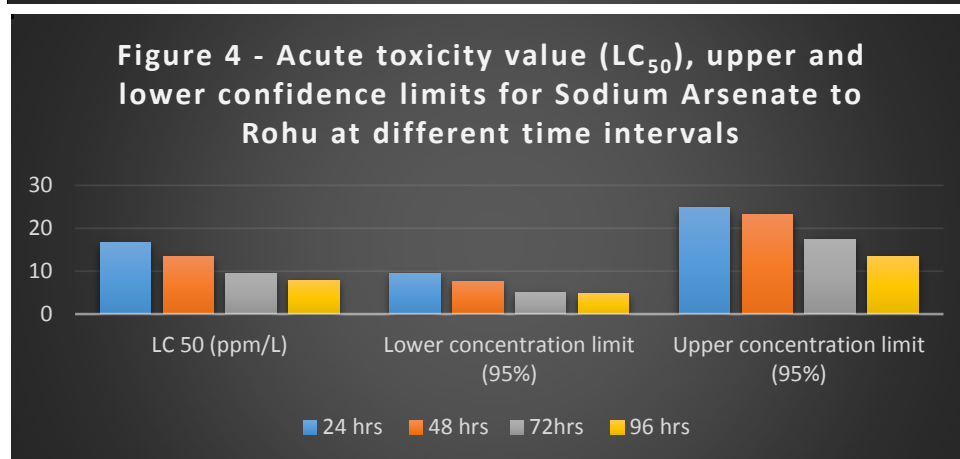
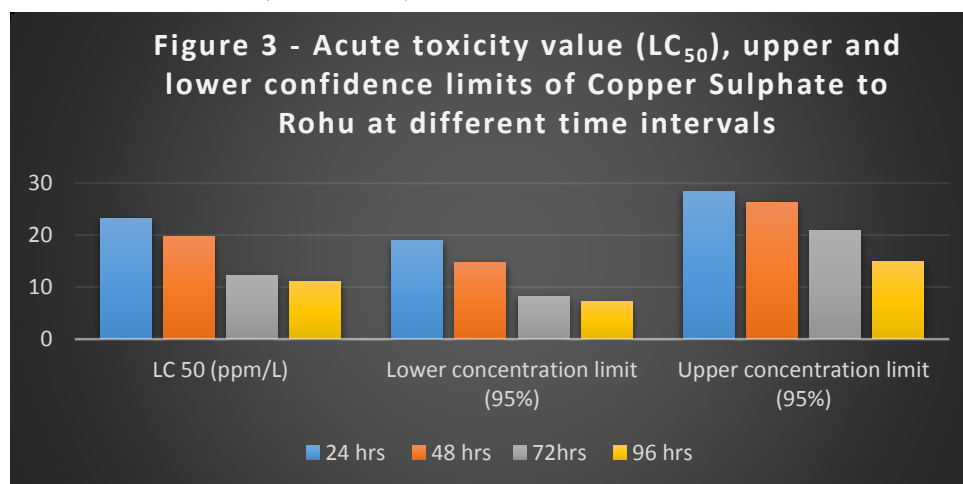
Water samples are collected from different spots of Hasdeo River in Korba District, Chhattisgarh India. Total 4 spots are selected for water sampling. Spot 1 was Belgiri Naala, Spot 2 was Dhengur Naala, Spot 3 was in Hasdeo downstream of Dhengur Naala and Spot 4 was Hasdeo Downstream of Ahiran River. From every spots 20 water samples were collected and total 80 water samples were used for study.

Table 1 -Heavy Metal analysis (mg/L)

Characteristic	Spot 1	Spot 2	Spot 3	Spot 4	Standard
Pb	0.045±0.056	0.051±0.021	0.027±0.080	0.043±0.023	0.01
Ni	0.040±0.012	0.019±0.076	0.028±0.056	0.021±0.008	0.02
As	5.9±1.23	4.3±0.45	3.7±0.87	2.2±1.86	0.3
Zn	0.9±0.02	1.12±0.78	0.2±0.09	0.8±0.02	5
Cr	0.067±0.12	0.031±0.26	0.029±0.02	0.019±0.04	0.05
Cu	0.25±0.18	0.21±0.12	0.19±0.04	0.21±0.08	0.05
Fe	5.92±2.01	5.11±1.86	3.65±0.96	4.08±1.20	0.3

Acute Toxicity

The LC₅₀ values along with their duration of exposure, lower and upper confidence limit of copper sulphate and sodium arsenate to the test fish Rohu (Labeo rohita).



The analysis of acute toxic effect and accumulation of heavy metal copper and metalloid arsenic in Rohu fish exposed to acute concentration of both toxicants revealed that metal uptake was directly correlated positively to the concentration of aquaria water. The study revealed that the bioaccumulation of heavy metal both in acute and chronic exposure was in varying degree in different tissue depending upon the type of metal, length of exposure and concentration of test metal in aquarium.

5. BEHAVIORAL RESPONSES

The behavioral changes of exposed fish were noted to renewal of water every 24h (acute) and 48h in chronic exposure for accurate parameters. Behavioral changes are sensitive indicators of pollutants such as sodium arsenate, copper sulphate and other heavy metal toxicants.

Table 2: Effect of Arsenic on Behavioral parameter Rohu fish for 1st day

Parameter number/min	Control	As 0.78 ppm	As 1.31 ppm
Operculum movement	72±0.48	78±0.80	84±0.24
S-shaped movement	2±8.0	4±1.4	3±0.12
Bottom dwelling activity	18±0.38	12±0.8	09±1.2
Jumping activity	1±0.6	2±1.2	2±1.8
Surfacing activity	6±0.20	8±1.2	9±0.8
Erratic behavior	2±0.22	3±0.66	4±0.4
Equilibrium status	Normal	Slightly loss	Much loss

Values are mean ± SE (N= 6) at P<0.05 significance level

Table 3: Effect of Arsenic on Behavioral parameter Rohu fish after 15th days

Parameter number/min	Control	As 0.78 ppm	As 1.31 ppm
Operculum movement	70±0.46	74±0.38	89±0.68
S-shaped movement	3±2.8	4±0.78	6±0.08
Bottom dwelling activity	17±0.58	12±1.8	10±0.6
Jumping activity	Absent	2±0.82	2±0.88
Surfacing activity	4±0.14	6±0.86	7±1.6
Erratic behavior	2±0.58	2±0.78	4±0.8
Equilibrium status	Normal	Slightly loss	Much loss

Values are mean ± SE (N= 6) at P<0.05 significance level

Table 4: Effect of Arsenic on Behavioral parameter Rohu fish after 30 days

Parameter number/min	Control	As 0.78 ppm	As 1.31 ppm
Operculum movement	68±1.22	72±1.12	80±0.52
S-shaped movement	1±0.64	2±0.44	4±0.12
Bottom dwelling activity	15±0.08	11±0.28	9±0.04
Jumping activity	Absent	1±0.08	2±0.06
Surfacing activity	3±1.2	2±0.34	5±0.68
Erratic behavior	1±0.16	2±0.22	3±0.66
Equilibrium status	Normal	Slightly loss	Much loss

Values are mean ± SE (N= 6) at P<0.05 significance level

Table 5: Effect of Arsenic on Behavioral parameter Rohu fish after 60 days

Parameter number/min	Control	As 0.78 ppm	As 1.31 ppm
Operculum movement	66±1.04	71±0.88	77±0.22
S-shaped movement	1±1.24	2±0.06	3±0.04
Bottom dwelling activity	14±0.46	10±0.64	7±0.12
Jumping activity	Absent	1±0.06	1±0.08

Surfacing activity	2±0.8	6±0.12	4±0.46
Erratic behavior	1±0.04	1±0.28	1±0.48
Equilibrium status	Normal	Slightly loss	Much loss

Values are mean ± SE (N= 6) at P<0.05 significance level

Table 6: Effect of Copper sulphate on Behavioral parameter of Rohu fish for 1st day

Parameter number/min	Control	Cu 1.10 ppm	Cu 1.84 ppm
Operculum movement	71±0.81	83±1.42	92±1.2
S-shaped movement	4±0.42	5±1.27	6±1.12
Bottom dwelling activity	22±4.41	15±0.74	13±2.32
Jumping activity	1±0.02	1±2.94	2±0.02
Surfacing activity	5±0.5	9±1.76	13±1.7
Erratic behavior	2±1.41	7±1.88	8±1.22
Equilibrium status	Normal	Slightly loss	Much loss

Values are mean± SE (N= 6) at P<0.05 significance level

Table 7: Effect of Copper sulphate on Behavioral parameter of Rohu fish after 15th day

Parameter number/min	Control	Cu 1.10 ppm	Cu 1.84 ppm
Operculum movement	73±1.07	75±0.43	77±0.9
S-shaped movement	2±0.29	3±0.09	4±0.07
Bottom dwelling activity	24±0.43	18±0.48	14±0.7
Jumping activity	2±0.68	3±0.82	4±0.4
Surfacing activity	6±0.6	11±0.15	14±0.68
Erratic behavior	2±0.04	4±1.2	4±0.89
Equilibrium status	Normal	Slightly loss	Much loss

Values are mean± SE (N= 6) at P<0.05 significance level

Table 8: Effect of Copper sulphate on Behavioral parameter of Rohu fish after 30 day

Parameter number/min	Control	Cu 1.10 ppm	Cu 1.84 ppm
Operculum movement	70±1.07	78±1.77	80±1.92
S-shaped movement	1±0.12	3±0.09	3±0.28
Bottom dwelling activity	20±0.24	17±1.59	11±1.6
Jumping activity	2±0.85	4±0.24	5±1.8
Surfacing activity	3±0.5	4±0.11	6±0.48
Erratic behavior	1±0.04	3±1.2	4±0.89
Equilibrium status	Normal	Slightly loss	Much loss

Values are mean± SE (N= 6) at P<0.05 significance level

Table 9: Effect of Copper sulphate on Behavioral parameter of Rohu fish after 60 day

Parameter number/min	Control	Cu 1.10 ppm	Cu 1.84 ppm
Operculum movement	71±0.12	73±0.72	76±0.33
S-shaped movement	1±0.29	2±0.23	3±1.21
Bottom dwelling activity	18±1.62	13±1.88	14±1.5
Jumping activity	Absent	1±0.11	1±0.0

Surfacing activity	3±0.3	4±1.5	4±0.09
Erratic behavior	2±0.23	4±0.44	4±1.5
Equilibrium status	Normal	Slightly loss	Much loss

Values are mean± SE (N= 6) at P<0.05 significance level

6. HISTOPATHOLOGICAL

The present study we microscopically examined the different tissues of fish to observe any metal induced abnormalities in control and treated group of fish Rohu. The efferent bronchial vessels, pre and posttrematic nerves lie in the groove of the bony arch. The primary gill lamellae are situated alternately on both sides of the interbranchial septum. It is consisting of centrally placed rod like supporting axis (SA) with blood vessels in either side. The secondary lamellae also termed as respiratory lamellae (RL), are higher vascularised and covered with thin layer of epithelial cells (EC).

In between the primary filaments and secondary gill lamellae is lined by a thick stratified epithelium. This region is consisting of the mucous cells and chloride cells. The surface is covered by epithelial cells which contain mucous cells. The gill filament is highly vascularized into which blood is circulated by means of primary and secondary afferent and efferent vessels. Fish exposed to sub-lethal concentration of both copper and arsenic showed changes in the histological architecture of liver.

After 30 days of exposure to sub-lethal concentration of metals hepatocytes started loosing their normal, polygonal shape and hepatocytes become irregular.

Necrosis of hepatocytes, degeneration in the islet of langerhans, hemorrhage and vacuolization were also found at various places. Distinct vacuolization of hepatocytes, dysplasia at some places and significant granulation in cytoplasm have been observed. After 60 days of exposure to both sub-lethal concentration of copper and arsenic, kidney architecture, showed many degenerative changes. After treatment the toxic damage is evident predominantly in the tubul es which exhibited various degenerative changes such as cytoplasmic vacuolization, dilation of their lumen and tubular epithelium with severe tubular necrosis and glomerular hypertrophy.

7. CONCLUSION

Experimental study that investigated the physico-chemical characteristics of aquarium water and the acute toxicity effects of copper sulfate and sodium arsenate on the fish species Rohu (Labeo rohita). The study observed various parameters including water temperature, pH, free CO₂, alkalinity, chloride levels, electrical conductivity, dissolved oxygen, hardness, and total dissolved solids, all of which were within permissible limits.

The main focus of the study was on acute toxicity testing, specifically the determination of median lethal concentrations (LC₅₀) of copper sulfate and sodium arsenate for the test fish species. The study found that as the concentration of these heavy metals increased, the mortality of the fish also increased. Additionally, the study investigated the behavioral responses of the fish to sub-acute concentrations of the two toxicants over different durations of exposure (1, 15, 30, and 60 days).

The exposed fish displayed abnormal behaviors such as increased feeding, restlessness, active swimming, and altered breathing patterns. There were also changes in schooling behavior, bottom dwelling activity, and jumping behavior in response to the toxicants.

The fish exhibited erratic swimming, loss of equilibrium, and physical injuries like wounds on the tail due to exposure to sodium arsenate. the pathological changes become more pronounced as compared to 30 days treatment of copper and arsenic, resulting into complete loss of polygonal shape of hepatocytes. kidney architecture, showed many degenerative changes. After treatment the toxic damage is evident predominantly in the tubul es which exhibited various degenerative changes such as cytoplasmic vacuolization, dilation of their lumen and tubular epithelium with severe tubular necrosis and glomerular hypertrophy. change in colour in gill lamellae from reddish to bluish brown with much coagulation of mucous and blood clots on gill lamellae were observed.

The study demonstrates how changes in water quality and the presence of toxicants can impact both physiological and behavioral aspects of fish species. This information can contribute to our understanding of the effects of pollution and contamination on aquatic ecosystems and guide environmental management and conservation efforts.

8. REFERENCES

- [1] Brown, V.M. and R.A. Dalton. (2011). The acute lethal toxicity to rainbow trout of mixtures of copper, phenol, zinc, and nickel. *J. Fish Biol.* 2:211-216.
- [2] Mukke, V.K. and Chinte, D.N. (2012) Effect of Sub Lethal Concentration of Mercury and Copper on Oxygen Consumption of Freshwater Crab, *Barytelphusa guerini*. *Recent Research in Science and Technology*, 4, 15- 17.
- [3] Ramesh, M. and Saravanan, M. 2010. Haematological and biochemical responses in a fresh water fish, *Cyprinus carpio* exposed to chloropyrifos. *Inter. J. Integra. Biol.*, 3: 80-83.
- [4] Venkataramana, P., Radhakrishnaiah, K. 2001. Copper influenced changes in lactate dehydrogenase and G-6-PDH activities of freshwater teleost, *Labeo rohita*. *Arch. Environ. Contam. Toxicol.* 67: 247-263.
- [5] Ebrahimi, M., Taherianfard, M. 2011. The effect of heavy metals exposure on reproductive systems of cyprinid fish from Kor River. *Iranian Journal of Fisheries Sciences*. 10(1): 13-24.
- [6] Das, B.K. and Mukherjee, S.C. 2001. Effect of Nuvan on haematology of rohu, *Labeo rohita* (Ham.). *Indian J. Fish.*, 48 (1): 85-92.
- [7] Benarjee, G., Narayana Rao, B., Srikanth, K. and Ramu, G. 2010. Haematological changes in the fresh water fish, *Channa punctatus* due to the effect of Rayon industry effluents. *Em International.*, 29 (1): 63-68.
- [8] Acharjee, M.L. and S. Barat (2012). Diversity of loach and catfish in a Darjeeling Himalayan hill stream their prospects as ornamental fish and constraints. *NBU journal of animal science* 6, 53-60.
- [9] Kumar, P., Sing, A. 2010. Cadmium toxicity in fish: An overview. *GERF Bulletin of Biosciences*. 1(1): 41-47.