
CURE OF TINEA CORPORIS BY INDIVIDUALISTIC HOMOEOPATHIC TREATMENT: A CASE REPORT

Sandip Samanta¹, Jaydebi Sarkar²

^{1,2}Madhav University, India.

Doi: <https://www.doi.org/10.58257/IJPREMS32167>

ABSTRACT

Tinea corporis is a fungal disease affects any part of our body or face. It is commonly called Ringworm due to its round or oval shape in most cases & the nature of spreading which is peripherally. It causes mild to moderate discomfort through itching & burning. It is contagious & very common problem in warm climatic conditions. Conventionally it is treated by antifungal ointments applied externally for 2 to 4 weeks. But several cases seen episodes of recurrence within 6 months & then they have to undergo same treatment, but sometime higher dose is needed, in obstinate cases oral antifungals are also given. But these oral antifungals have several side effects – from allergic reactions to internal bleeding. Here we have treated a tinea corporis case of a 21yr male student successfully through individualised homoeopathic treatment & observed 10 months for recurrence. After successful treatment within 10 months tinea never reappeared.

Keywords: Tinea, Case report, Homoeopathy, Individualised treatment, Antifungal, Itching

1. INTRODUCTION

Tinea corporis is a type of Tinea infection caused by dermatophytes. It is also colloquially called Ring worm due to its round shape & elevated margin, also it spreads peripherally. The other common types of Tinea include Tinea capitis or Scalp ringworm, Tinea unguium or Onychomycosis, Tinea cruris or Jock itch, Athlete foot or Tinea pedis. The shape of Tinea corporis is annular. Usual investigation of Tinea includes KOH. ^[1] It generally affects the glabrous skin surface or non-hairy areas of skin. Its border is well defined & active, consists of papulo-vesicular eruptions. Central part of the lesion may show hyperpigmentation, erythema & scaling. Though any part of body surface can be affected, belt area is most affected due to friction, especially in females. In India most of the cases of Tinea corporis is caused by *Trichophyton rubrum*. Sometimes after application of topical steroid ointments classical clinical features are gone & diagnosis becomes difficult; it is then called Tinea incognito. ^[2] Tinea corporis sometimes considered as dermatophyte infection of smooth skin. It sometimes misdiagnosed as discoid eczema or pityriasis rosea. ^[3] Tinea faciae & Tinea barbae are the variants of Tinea versicolor. Tinea faciae appears as Annular or serpiginous erythematous scaly patches on face & Tinea barbae present as inflammatory swelling with fall of hair in beard area. ^[4] In young children most common causative fungus of Tinea corporis is *M. canis*, mostly acquired from pets; whether in older children it is caused by *T. rubrum*, *T. verrucosum*, *T. mentagrophytes*, *T. tonsurans*, *Epidermophyton floccosum*. Close personal contacts to patients with Tinea pedis or tinea unguium sometimes acts as a source. Its predisposing factors include, humid warm climate, immunodeficiency states, diabetes mellitus. It first appears as one or two annular lesion & then coalesce to form polycyclic border & thus propagates. The lesion creates confusion with Pityriasis rosea, Seborrheic dermatitis, Psoriasis, Numular eczema, Annular erythema. ^[5] Secondary pyogenic infection on the lesion may be noticed due to repeated scratching & disseminated infection may be seen in immunocompromised individuals. Homoeopathic approach to treat Tinea corporis is always constitutional as the disease buds over underlying miasms & mostly it is under the domain of tubercular miasm; sometimes intercurrent use of nosodes help to cure speedily. ^[6] Richard Huges used *Sepia* for ringworm called *Herpes circinatus* in most of the cases with fair success, then after proving of *Tellurium* he began using it & speedily cured the ringworm cases. ^[7] Dr. Burnett also suspected Ringworm might be a disease of tubercular origin. He saw ringworm cases of every child in a family with tubercular history. He cured many ringworm cases with anti-tubercular medicines given internally in dynamic doses. ^[8]

2. CASE PRESENTATION

A male student of 21yr came to OPD of B.G. Garaiya Homoeopathic Medical College & Hospital with complaint of a Round patchy scaly erythematous eruption with elevated border on neck associated with occasional itching. It was previously treated homoeopathically with little success. No special modalities are found.

Past history: Recurrent diarrhoea in childhood

Family history: Father has hypertension & stroke; Mother has vitiligo; Grandfather & Grandmother has hypertension.

Personal history: patient is too much laborious, helping nature, always busy in family business, study at night only, good at study.

Generalities

Patient is tall, well built, with black well grown hair. His appetite is good, but irregular diet habit, does not have much complaint in case of skipping meal. He has no particular food desire or aversion. Thirst is moderate. Perspiration is much, over whole body when in exertion, non-offensive. Bowel movement regular, no complaint about urination. Patient can tolerate extreme heat & cold with ease.

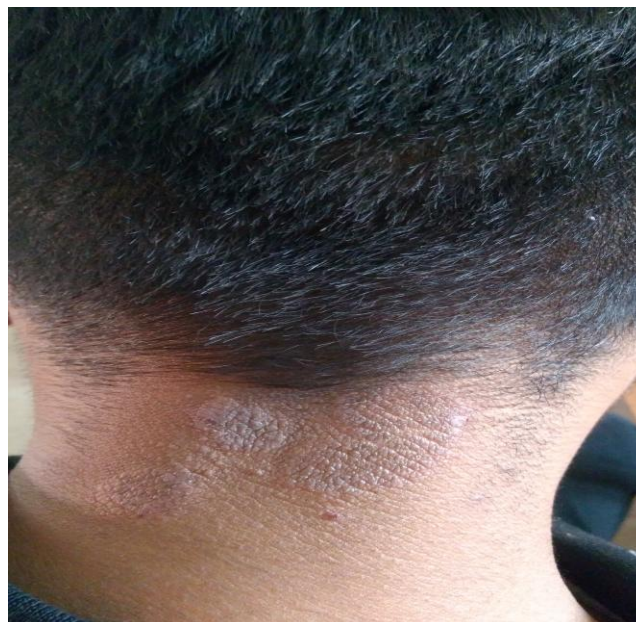Mentally patient is very active. Can work full day without tiring, both mental & physical. Anxious about well-being of his family; become very anxious if someone gets ill.

Therapeutic intervention & follow up

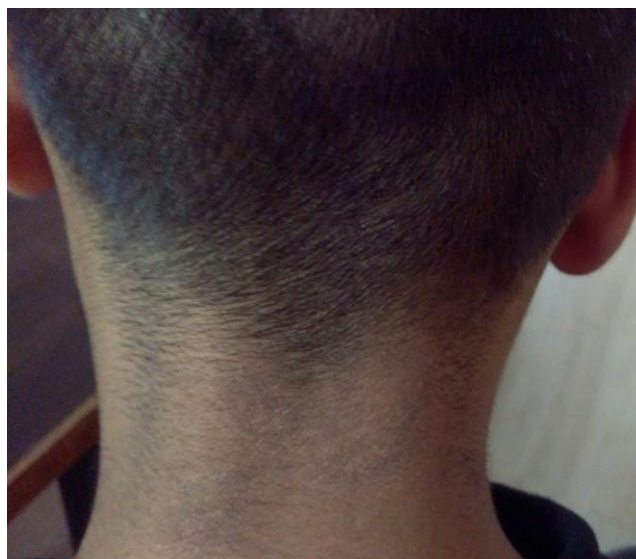
On the basis reportorial analysis & after the consultation of materia medica Sanicula 200 was given. After 1-month patient reported his skin is now smooth without eruption, without itching. Then 3 months after initial prescription recurrence occur with eruption & itching. Sanicula 200 repeated. After 1 month he reported no amelioration, a fresh case was taken, but symptomatology was similar except changeableness of mind gone, consulting the materia medica Fluoric acid 200 given. He reported after 1-month that his skin became normal, no eruption or itching. He then asked to report after 6 months, no recurrence, skin remain normal throughout. Patient was then asked to report if any recurrence occurs. After 10 months elapsed, patient was asked if any recurrence is there or any other symptom occur, but patient says he is completely fit now. Photographs are taken at each stage for documentation.

Photographs

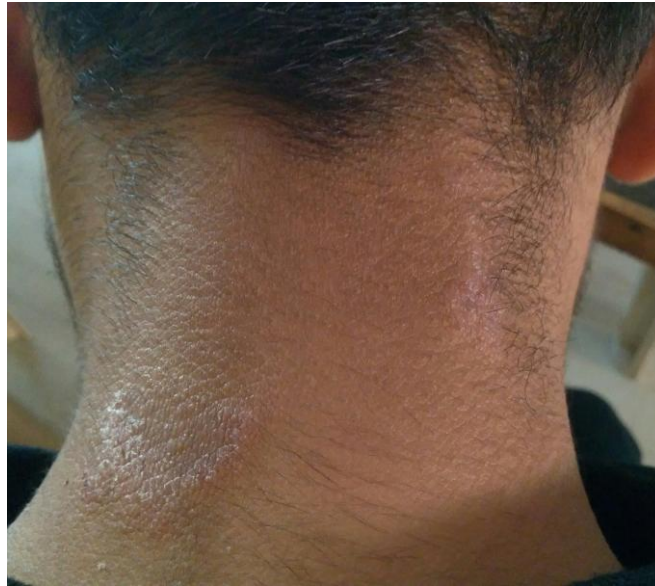1st visit



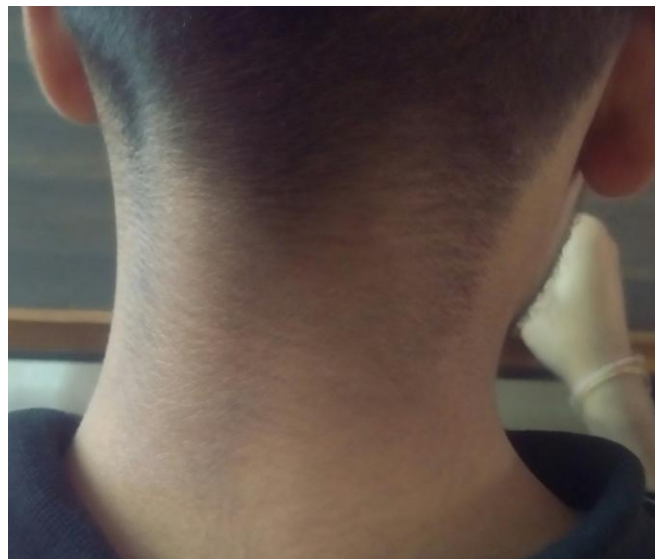2nd visit: After Sanicula 200



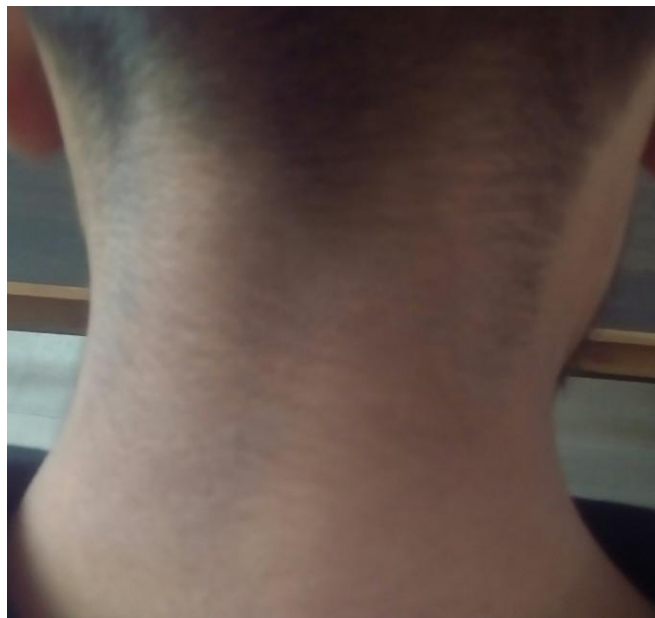3rd visit: Reappearance



4th visit: After Fluoric acid 200



5th visit: After 6 months



3. DISCUSSION

After extensive search of international databases, we found some evidence based cases of Tinea corporis treated by Homoeopathy. A case report published in Homoeopathic links, 2022, by Deepti Dewan which is treated by Individualistic homoeopathic treatment with medicine Sulphur 200C followed by Tellurium 30C.^[9] A prospective longitudinal study on Tinea published in Researchgate, March 2021, by Gupta Y, Tuteja S, Acharya A & Tripathy V where 63% of patients shown improvement through homoeopathic treatment.^[10] In modern medicine treatment of tinea includes topical antifungals, & sometimes topical corticosteroids; these medicines are sometimes given internally. In homoeopathy only internal medication is given with very small dose & the right medicine can successfully cure such cases without recurrences as shown above.

4. CONCLUSION

The above illustrated case is an example of successful treatment of Tinea corporis. Hereby we can assert that through right homoeopathic medications we can cure such cases without recurrence & any side effects.

Consent

Author has taken necessary consent from patient before publishing his case & associated photographs. The necessary efforts are taken to conceal the patient's identity also, but anonymity cannot be guaranteed.

Financial support or sponsorship

None

Conflict of interest

Nothing declared

5. REFERENCES

- [1] Hordinsky MK, Soutor C; Clinical Dermatology 1st ed., LANGE, ISBN: 978-0-07-177296-9 p5-20
- [2] Pasricha JS, Verma K; Treatment of Skin Diseases, 6th ed, JAYPEE publishers, ISBN: 978-93-5090-456-5, p123-125
- [3] Faculty of Bhatia Medical Institute; Textbook of Dermatology, 2012; Dr. Bhatia Medical Institute; p28
- [4] Khanna Neena, Illustrated Synoipsis of Dermatology & Sexually transmitted Diseases, 5th ed, ELSEVIER India, ISBN: 978-81-312-4230-8; p304-305
- [5] Imandar C. Arun, Palit Aparna, Raghunatha S; Textbook of Pediatric Dermatology, 2nd ed, JAYPEE Brothers, ISBN: 978-93-5152-083-2; p229
- [6] Master J.Farokh, Skin Homoeopathic Approach to Dermatology, 2nd ed, B. Jain Publishers, ISBN: 978-81-319-0716-0; p369, 717
- [7] Huges Richard, A Manual of Therapeutics: According to the Method of Hahnemann, 2nd ed. 1877, Leath & Ross Pub, London. P361
- [8] Burnett J.C. Ringworm; its constitutional nature & cure, B. Jain publishers, 2001, ISBN: 81-7021-681-8; p10-11
- [9] <https://www.thieme-connect.com/products/ejournals/abstract/10.1055/s-0041-1734199>
- [10] https://www.researchgate.net/publication/350129029_Effectiveness_of_Homoeopathy_in_Tinea_corporis_and_Tinea_cruris_-_A_Pro prospective_Longitudinal_Observational_Study