

FASCIOLIASIS

Nandini Ambekar¹

¹Osh State University

DOI: <https://www.doi.org/10.58257/IJPREMS37907>

ABSTRACT

Fascioliasis, commonly known as liver fluke disease, is a parasitic infection that affects both humans and animals. It is caused by flatworms *Fasciola hepatica* and *Fasciola gigantica*—that primarily target the liver and bile ducts. While fascioliasis is often associated with livestock like sheep and cattle, humans can also contract it, making it an important public health concern.

The World Health Organization (WHO) has classified fascioliasis as a neglected tropical disease (NTD). This means it affects millions of people, particularly in poorer regions, but often doesn't get enough attention or resources for prevention and treatment.

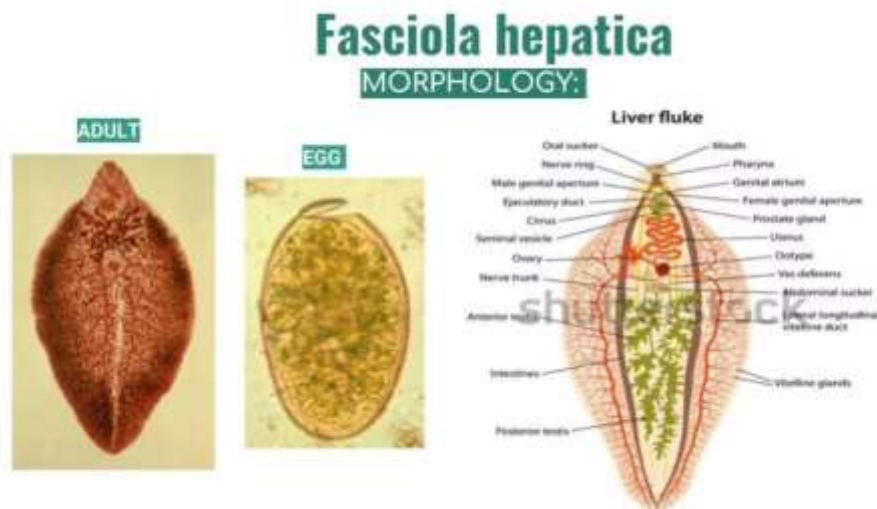
This article explains what fascioliasis is, how it spreads, its symptoms, how it's diagnosed and treated, and what can be done to prevent it.

1. INTRODUCTION

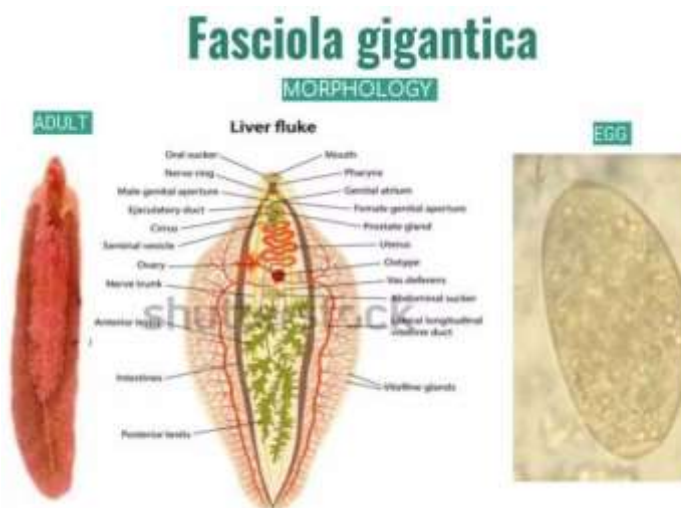
What Causes Fascioliasis?

Fascioliasis is caused by two species of parasitic worms:

1. *Fasciola hepatica* – Also called the "sheep liver fluke," this species is found in temperate regions like Europe, the Americas, and parts of Asia.



2. *Fasciola gigantica*— This larger species is more common in tropical and subtropical areas, such as Africa and parts of Asia.

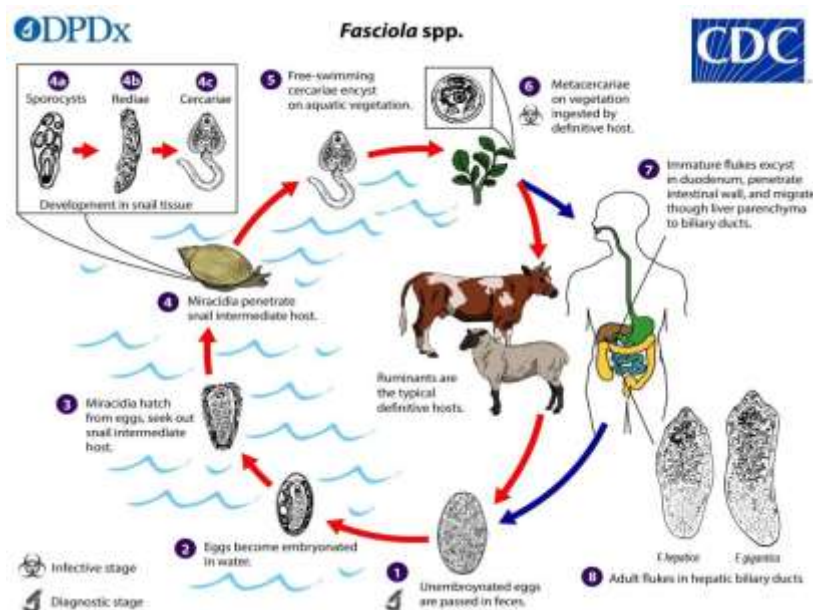


Both types are similar in the way they infect humans and animals, but they differ slightly in size and where they're most commonly found.

How Does Infection Happen?

Fascioliasis has a complicated life cycle, but it all starts in water.

- 1. Egg Stage:** Adult worms living in the bile ducts of infected animals lay eggs, which pass out of the body in feces. If the feces get into water, the eggs hatch into larvae.
- 2. Larval Stage:** The larvae swim in the water and look for freshwater snails, which act as hosts. Inside the snail, the larvae multiply and develop further.
- 3. Cercariae and Metacercariae:** After leaving the snail, the larvae attach themselves to water plants, forming a protective cyst called a metacercaria.
- 4. Infection in Humans or Animals:** When humans or animals eat contaminated plants like watercress or drink water with metacercariae, they swallow the cysts. Once inside the body, the parasites make their way to the liver, where they mature into adult worms.



The entire process, from egg to adult worm, can take about three to four months.

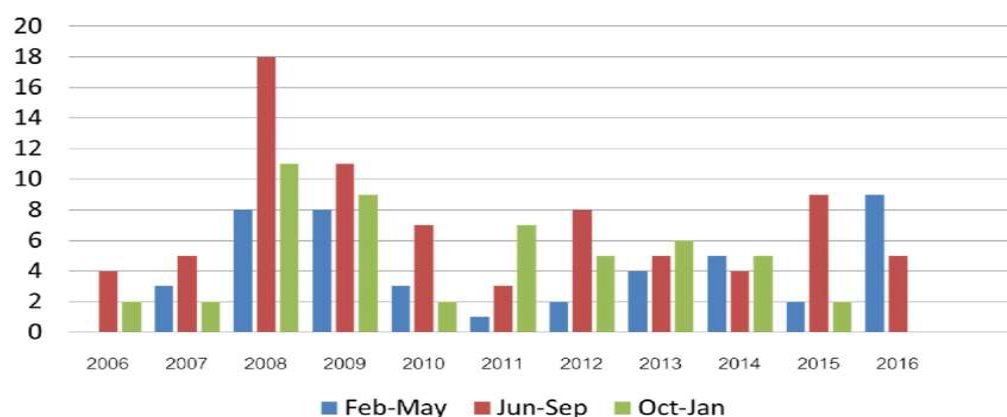
Where Is It Found?

Fascioliasis occurs worldwide, but it's most common in areas where people rely on livestock for farming and where freshwater plants like watercress are consumed.

- High-risk regions include parts of South America, Africa, and Southeast Asia.
- Poor sanitation and access to untreated water increase the risk of infection.
- It's estimated that over 2.4 million people are infected globally, and many more are at risk.

Livestock, including sheep, cattle, and goats, are frequently infected, leading to economic losses due to reduced productivity, weight loss, and liver damage.

Number of case

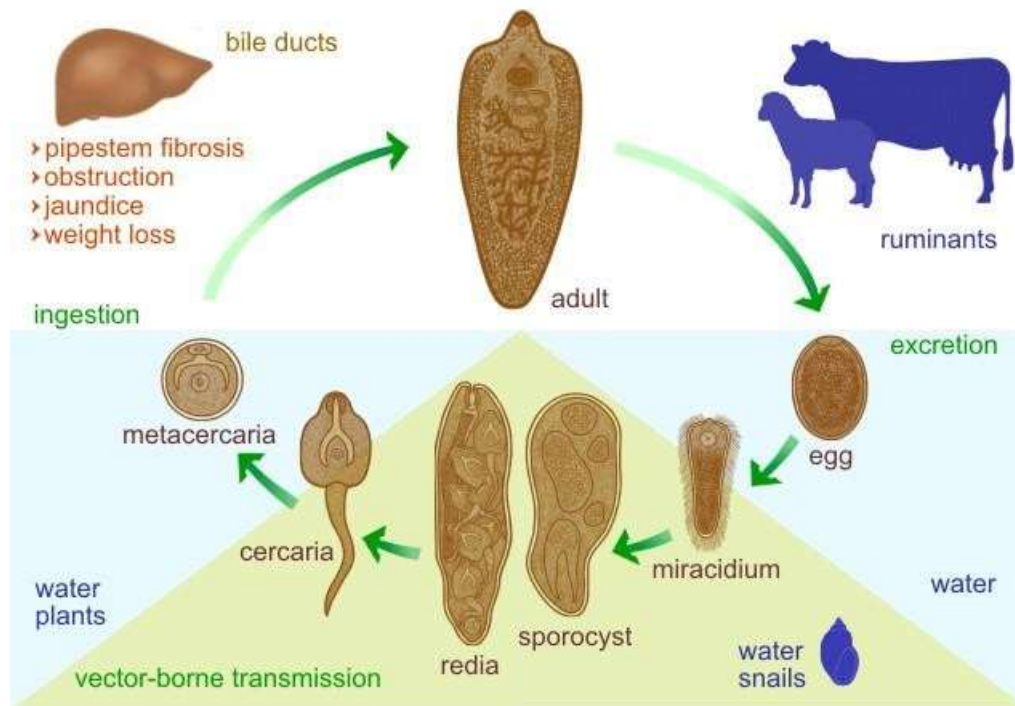


What Happens After Infection?

Fascioliasis can be divided into two stages, depending on the parasite's activity in the body:

1. Acute Stage:

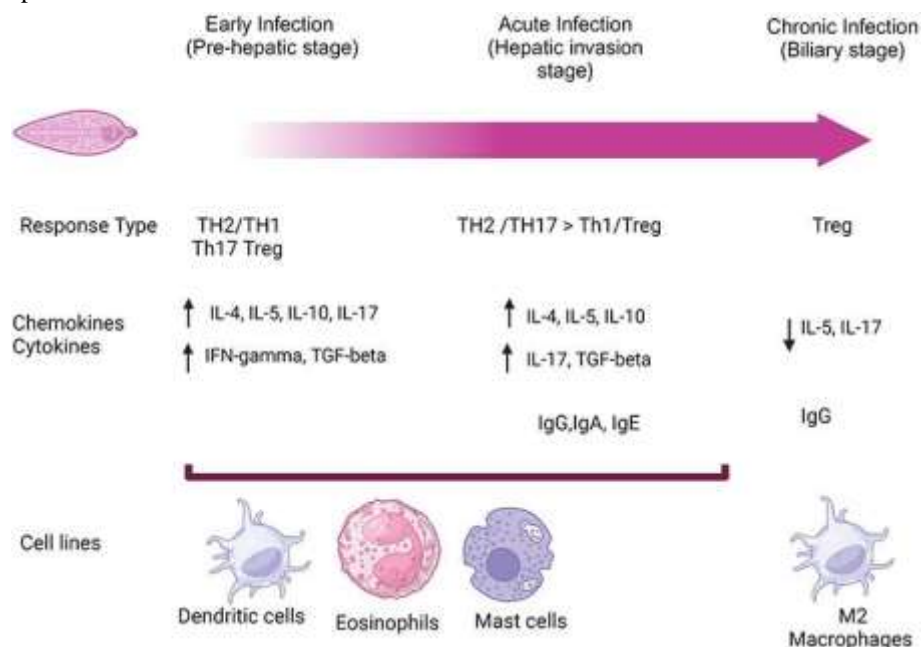
- This occurs when the immature worms migrate through the liver tissue, causing damage as they move.
- Symptoms include fever, chills, nausea, vomiting, and severe abdominal pain, especially in the upper right side.
- The liver may become swollen (hepatomegaly), and blood tests often show an increase in eosinophils, a type of white blood cell that responds to parasites.



2. Chronic Stage:

- Once the worms settle in the bile ducts, they can live there for years, feeding on bile and causing long-term inflammation.
- Symptoms may include persistent abdominal pain, jaundice, fatigue, and weight loss.
- In severe cases, the bile ducts may become blocked, leading to liver damage or secondary infections.

Rarely, the parasites may wander outside the liver and end up in unusual places like the lungs, skin, or brain, causing more serious complications.



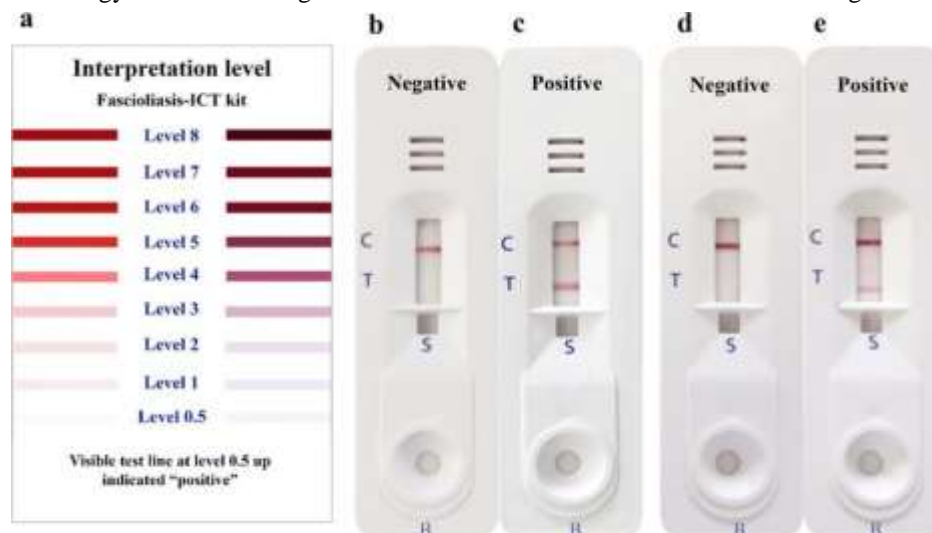
How Is It Diagnosed?

Diagnosing fascioliasis can be tricky, especially in the early stages when symptoms are vague.

- Blood Tests: High levels of eosinophils and liver enzymes often point to a parasitic infection.
- Stool Samples: Eggs from the parasites can sometimes be found in stool, but this only works during the chronic phase when adult worms are present.
- Antibody Tests: Blood tests like ELISA can detect antibodies against the parasite, Antibody detection assays are particularly useful in:-
- The early stages of infection before eggs are produced (egg production typically begins at least 3 to 4 months after exposure)
- Chronic infection when egg production is sporadic or low Loss of detectable antibodies occurs 6 to 12 months after cure.

In chronic infections, eggs may be recovered from the stool or from duodenal or biliary materials. The eggs are indistinguishable from those of *Fasciolopsis buski*.

- The *Fasciola hepatica* ELISA kit is intended for the quantitative detection of IgG antibodies against *Fasciola hepatica* in human serum. Serology is an aid for diagnosis and cannot be used as the sole method of diagnosis.



- Imaging Tests: Ultrasounds or CT scans may reveal liver damage or bile duct blockages caused by the worms.

Table 1: Clinical and radiological Features of proved cases of *Fasciola hepatica*.

Case No	1	2	3	4
Age/Sex	25/F	43/F	35/F	71y/m
Occupation	Housewife	Housewife	Housewife	Retired
Consumption of raw vegetables	Yes	Yes	Yes	Yes
Clinical features	RH pain 1 year, Fever 3 months, Weight loss 8 kg in 1 year	RH pain 6 months	RH pain 6 months, loss of weight 7 kgs in 6 months	RH pain 1 Year
AEC at start of treatment	1080	1056	2086	2548
Abnormal lab findings	None	None	WBC 14900, Eosinophil 14 %	None
CT Abdomen at start of treatment	Fasciola cluster of grapes sign positive segment 8, 5.3 X 4.7 cm. Linear filling defects in ducts. CBD filling defects.	Fasciola cluster of grapes sign positive segments 5, 6 and 7. Measuring 9 X 10 cm. CBD lucent filling defects. Mild intrahepatic biliary dilatation.	Fasciola cluster of grapes sign positive segments 4a, 8 and 2 measuring 8cm. Segmental bile ducts dilated with filling defects. CBD mildly dilated with filling defects.	Fasciola cluster of grapes sign positive in right lobe of liver
Stool examination	No ova or parasites	No ova or parasites	No ova or parasites	No ova or parasites
Bile examination	Adult dead worm of Fasciola	Adult dead worm of Fasciola	Adult dead worm of Fasciola	Adult dead worm of Fasciola
Nitazoxanide	500 mg TDS x 14 days	500 mg TDS x 14 days	500 mg TDS x 14 days	500 mg TDS x 14 days
Other medication	Ivermectin 12 mg OD x 7 days	None	None	None
Repeat Imaging after therapy	Not done	USG done 8 months later - reduction in size of cystic lesions from 10 cm to 4.5cm.	CT 3 months later - significant reduction in size from 8cm to 3cm with no dilatation of CBD.	Not done
AEC 3 months after therapy	288	530	Not done	Not done

RH - right hypochondriac, AEC - absolute eosinophil count range 30-350 cells/cu mm, ALP - serum alkaline phosphatase range 45 to 115 U/L, GGTP range 10-50 U/L, SGOT range 5-40 U/L, SGPT range 5-35 U/L.

Treatment Options

Fortunately, fascioliasis can be treated effectively with antiparasitic medications.

1. Triclabendazole:
 - This is the drug of choice, effective against both immature and adult worms.
 - For patients ≥ 6 years of age is with 2 doses of 10 mg/kg triclabendazole given 12 hours apart, orally with food. Nitazoxanide 500 mg orally twice a day for 7 days may be effective
2. Alternative Treatments:
 - Drugs like bithionol and nitazoxanide may be used if triclabendazole isn't available.
3. Symptomatic Relief:
 - Painkillers and anti-inflammatory medications can help manage symptoms.
 - Antibiotics may be needed if secondary bacterial infections develop.
4. Surgery:
 - Rarely, surgery is required to remove bile duct obstructions or drain liver abscesses.

Complications

Severe anemia and, less commonly, pancreatitis, occur in children more frequently than in adults.

Rare complications include ectopic foci of infection, hemoperitoneum, subcapsular hematoma, hepatic mass, cholecystitis, ascending cholangitis, biliary obstruction, , Liver scarring (fibrosis).

How Can It Be Prevented?

Preventing fascioliasis requires a combination of public health interventions and personal precautions:

1. Safe Eating and Drinking Habits:
 - Avoid eating raw water plants, especially in areas where fascioliasis is common.
 - Always boil or filter drinking water in endemic areas.
2. Livestock Management:
 - Deworm animals regularly and keep grazing areas clean to reduce contamination.
3. Snail Control:
 - Use chemicals or environmental management techniques to control snail populations in water bodies.
4. Public Education:
 - Teach people about the risks of eating raw aquatic plants and encourage better sanitation practices.

Economic Impact:-

Infected livestock produce less milk, meat, and wool, causing economic losses for farmers. Additionally, human infections lead to lost productivity, medical costs, and the need for long-term care in some cases. Controlling fascioliasis not only improves health but also boosts agricultural productivity.

Final Thoughts:-

Fascioliasis may not be as well-known as other parasitic diseases, but it can have serious health and economic consequences. With effective medications like triclabendazole and preventive strategies such as proper food handling and snail control, it's possible to reduce the burden of this disease.

However, more awareness, research, and support from governments and organizations are needed to tackle fascioliasis effectively. By combining medical treatments with education and better sanitation, we can protect both human and animal health.

2. REFERENCES

- [1] Mas-Coma S, Bargues MD, Valero MA. Fascioliasis and other plant-borne trematode zoonoses. *Int J Parasitol*. 2005.
- [2] WHO. Fascioliasis. Available at: www.who.int
- [3] Keiser J, Utzinger J. Emerging foodborne trematodiasis. *Clin Microbiol Rev*. 2009.
- [4] Torgerson PR, Claxton JR. Epidemiology and control of liver flukes in cattle and sheep. *Vet Parasitol*. 1999.
- [5] Marcos LA et al. Fasciola hepatica infection: clinical spectrum and treatment response. *J Infect Dis*. 2008.
- [6] Fairweather I, Boray JC. Fasciolicides: efficacy, actions, and resistance. *Parasitology*. 1999.