

# A COMPREHENSIVE REVIEW OF AGE-RELATED MACULAR DEGENERATION SEGMENTATION FROM FUNDUS IMAGES

J. Jency<sup>1</sup>, S. Shunmugan<sup>2</sup>

<sup>1</sup>Research Scholar, Department of Computer Science, S. T. Hindu College, Nagercoil, Affiliated to Manonmaniam Sundaranar University, Tirunelveli, India.

<sup>2</sup>Associate Professor, Department of Computer Science and Applications, S. T. Hindu College, Nagercoil, Affiliated to Manonmaniam Sundaranar University, Tirunelveli, India.

jencysekar1995@gmail.com, shunsthc@gmail.com

## ABSTRACT

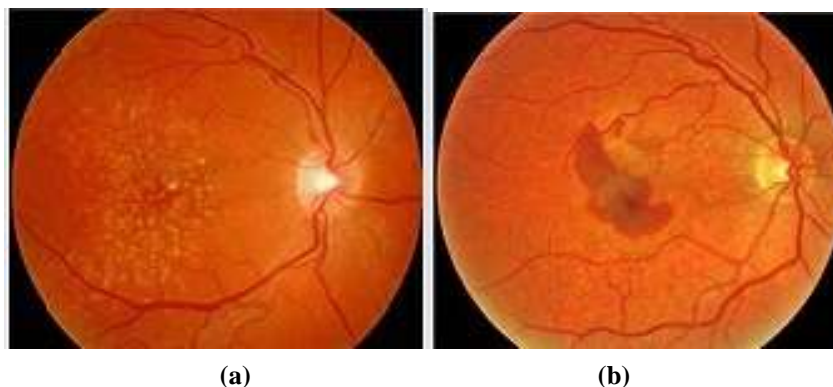
Age-related Macular Degeneration (AMD) is an eye disease that damages the macula, causing central vision loss, especially in older adults. AMD is a major cause of central vision loss in people over 50, and early detection can help slow development and preserve vision through medical treatments, lifestyle modifications, or treatments. For this reason, it is imperative to focus on diagnosing AMD. Effective management of AMD depends on early fundus imaging detection and classification. The state-of-the-art methods for AMD segmentation from fundus images are reviewed in this study, with an emphasis on both current Deep Learning (DL) algorithms and conventional image processing methods. It offers a comprehensive evaluation of different segmentation methodologies and their applicability in medical applications. The obstacles, limitations, and future paths in this quickly developing sector are also covered.

**Keywords:** Age-related Macular Degeneration, Fundus Imaging, Deep Learning, Image Segmentation, Convolutional Neural Networks (CNNs).

## 1. INTRODUCTION

Early detection of vision-threatening disorders such as Glaucoma, Cataracts, and Macular Degeneration (MD) depends on eye diagnostics, which enables prompt treatment to stop vision loss. Since many illnesses show up in the eyes, it also aids in the diagnosis of systemic ailments including diabetes, high blood pressure, and neurological disorders. Frequent eye exams help with early detection of ocular and systemic disorders, enhance quality of life, and guarantee general eye health.

Ophthalmology relies heavily on medical imaging for diagnosing and managing eye diseases. Advanced imaging techniques like Optical Coherence Tomography (OCT), Fundus Photography, Fluorescein Angiography (FA), and ultrasound biomicroscopy provide detailed views of ocular structures, enabling early detection of conditions such as glaucoma, diabetic retinopathy, macular degeneration, and retinal detachment. These imaging modalities enhance precision in treatment planning, disease monitoring, and surgical outcomes, improving overall patient care in ophthalmology.



**Fig. 1: (a) Dry macular and (b) Wet macular**

AMD [1] affects the central retina, known as the macula, leading to progressive vision loss. AMD can be categorized into two forms: Dry (atrophic) and Wet (neovascular) [2]. Figure 1(a) exposes the Dry macular and Figure 1(b) Wet macular regions. The detection and segmentation of AMD-related features in fundus images, such as Drusen, Geographic Atrophy (GA), and Choroidal Neovascularization, are essential for diagnosis and monitoring. There are two primary signs of the progressing condition: Dry and Wet AMD. Herein, the Dry AMD In general, dry AMD is less severe than wet AMD and is more common. AMD occurs when the retina's macula area gets thinner. Dry type AMD patients have cellular debris called drusen in their macula, which progressively destroys light-sensitive cells and affects

vision. The three phases of dry AMD are early, intermediate, and late. The Wet AMD It is caused by abnormal blood vessel growth in the eye, which damages the macula. Herein, the retina leaks blood and fluid due to the growth of blood vessels behind the macula. Wet AMD is regarded as dangerous as it might result in sudden visual loss.

Fundus photography is a non-invasive imaging technique used to capture detailed images of the interior surface of the eye, specifically the retina, Optic Disc (OD), macula, and blood vessels. This diagnostic tool is essential for detecting and monitoring a variety of eye conditions, including Diabetic Retinopathy (DR), MD, Glaucoma, and Retinal vascular disorders. The manual analysis of these images is time-consuming and prone to inter-observer variability. Automated segmentation techniques have emerged to address these challenges, leveraging advancements in image processing and Machine Learning (ML). This paper explores the various methodologies used for AMD segmentation, highlighting their strengths and weaknesses

## 2. IMAGE PROCESSING TECHNIQUES FOR AMD

Traditional image processing techniques for AMD segmentation rely on manual feature extraction and rule-based algorithms. These methods include:

### 2.1 Thresholding

Thresholding is one of the simplest techniques, where pixel intensity values are compared against a threshold to segment features like drusen. While effective for high-contrast images, thresholding struggles with varying lighting conditions and complex structures.

Thresholding for AMD segmentation in fundus images involves several steps to accurately separate areas affected by the condition. The process begins with preprocessing, where the image is normalized and contrast is enhanced using methods like histogram equalization or CLAHE [3], [4] to make features like Drusen more visible. The image is then converted to grayscale to simplify the thresholding process. Next, an appropriate threshold value is chosen to distinguish the regions of interest (affected areas) from the background. This can be done using manual thresholding, Otsu's method, or adaptive thresholding, depending on the image characteristics. After thresholding, the image is segmented, with the foreground representing areas indicative of AMD, such as drusen or pigmentary changes. Post-processing techniques like morphological operations are applied to clean the segmented regions by removing noise and filling gaps. The result is a clearer representation of the AMD-affected areas, which can be further refined through connected component analysis and contour extraction to analyze the size, shape, and location of the detected abnormalities for diagnosis and monitoring.

### 2.2 Edge Detection

In the Edge detection methods, the Canny and Sobel operators, are used to identify boundaries of AMD-related features. These techniques are useful for outlining drusen and atrophy but may produce noisy results in images with poor contrast. Edge detection techniques for AMD segmentation from fundus images begin with preprocessing, where contrast enhancement techniques like histogram equalization are applied to improve the visibility of AMD features. The image is then converted to grayscale to simplify the edge detection process. Common edge detection algorithms, such as the Canny or Sobel operator, are applied to identify boundaries of key features like drusen or pigmentary changes associated with AMD. Once edges are detected, morphological operations such as dilation or erosion refine the edges and close any gaps. A threshold is then applied to the edges to segment regions of interest. Contours are extracted from the edge-detected image to outline AMD features, which are isolated by identifying closed boundary contours. Post-processing operations like closing or filling are used to further refine the segmented regions. Finally, the segmented AMD regions are analyzed by measuring their size, shape, and location, which helps in diagnosing and monitoring the progression of the disease.

### 2.3 Region Growing

Region growing algorithms start from a seed point and expand based on pixel similarity. This method can effectively segment homogeneous areas like drusen but may fail in heterogeneous regions, such as those affected by wet AMD.

Region growing for AMD segmentation in fundus images involves starting with a seed point, typically chosen from a region likely to contain AMD features, such as drusen or macular changes. The algorithm then iteratively adds neighboring pixels to the seed region based on predefined similarity criteria, such as intensity or texture. The process continues until a predefined condition is met, like a maximum similarity threshold or when neighboring pixels no longer match the characteristics of the region. Preprocessing steps, such as contrast enhancement and noise reduction, are usually applied beforehand to improve the accuracy of region growth. Morphological operations may follow to refine the segmented region, removing small artifacts or filling in gaps. The algorithm ensures that only connected areas with similar characteristics are included in the segmented region, effectively isolating the AMD features. Post-segmentation

analysis includes measuring the area, shape, and distribution of the segmented regions, which is valuable for diagnosing and tracking the progression of AMD. The technique is especially useful when there are distinct, homogenous regions affected by the disease.

## 2.4 Morphological Operations

Morphological operations like dilation, erosion, opening, and closing are used to refine segmented regions. These techniques help remove small artifacts and improve the definition of features but require careful parameter tuning.

Morphological operations are often applied in AMD segmentation to refine and enhance the accuracy of detected features in fundus images.

After initial segmentation (e.g., thresholding or edge detection), operations like dilation and erosion are used to improve the boundaries of regions of interest, such as drusen. Dilation helps expand the detected regions by adding pixels to the boundaries, which can be useful for closing small holes or gaps in the segmented area. Erosion, on the other hand, reduces the region's size by removing pixels from the boundaries, helping eliminate small noise or irrelevant features. Opening (erosion followed by dilation) and closing (dilation followed by erosion) operations are also frequently applied to remove small artifacts or connect fragmented regions, improving the continuity of the segmentation. These morphological operations help produce a cleaner, more accurate representation of the AMD regions, allowing for better feature analysis and more reliable diagnosis. The result is a more precise segmentation of AMD features, which aids in assessing the severity and progression of the condition.

## 3. MACHINE LEARNING (ML) APPROACHES

ML has significantly improved AMD segmentation by automating feature extraction and learning complex patterns from data [5][6].

### 3.1 Support Vector Machines (SVMs)

SVMs [7] have been used for classifying retinal features based on handcrafted features. Although they improve accuracy over traditional methods, SVMs require extensive feature engineering and large labeled datasets.

SVM is a powerful technique used for AMD segmentation in fundus images by classifying pixels into distinct regions, such as healthy tissue and areas affected by AMD.

The process begins by extracting relevant features from the fundus image, such as intensity, texture, or shape characteristics of the regions of interest (e.g., drusen or macular abnormalities).

These features are then used to train an SVM model, where a hyperplane is learned to separate the pixels of different classes. The SVM algorithm maximizes the margin between these classes, ensuring clear delineation between normal and abnormal areas. Once trained, the SVM model is applied to the image to classify each pixel based on its feature set. The segmentation result is a binary or multi-class map, highlighting the AMD-affected regions. Post-processing techniques like morphological operations may be applied to refine the segmentation. SVM is particularly effective for complex segmentation tasks as it can handle non-linear boundaries between classes with the use of kernel functions. The final segmented regions allow for accurate analysis of AMD features, aiding in diagnosis and tracking disease progression.

### 3.2 Random Forests (RF)

Random Forests provide robust classification by aggregating predictions from multiple decision trees. They have been applied to AMD segmentation with moderate success but are limited by their reliance on feature engineering.

RF is an ensemble ML technique used for AMD segmentation in fundus images by classifying pixels based on various features. First, relevant features such as color, texture, intensity, and shape are extracted from the image to describe potential AMD-related regions, like drusen or pigmentary changes. These features are then used to train multiple decision trees, each learning different patterns within the data.

The Random Forest algorithm aggregates the results of all decision trees to make a final classification decision, ensuring robustness and reducing overfitting. Each tree in the forest independently classifies pixels, and the majority voting approach determines the final class for each pixel.

After training, the RF model is applied to segment the image, labeling regions as either affected by AMD or normal. Post-processing steps, such as morphological operations, can refine the segmentation by removing noise or filling gaps. Random Forests can effectively handle large, complex datasets and are less sensitive to noise, making them a reliable method for accurately segmenting AMD features. This technique helps in assessing the extent of AMD and tracking its progression over time.

## 4. DEEP LEARNING (DL) TECHNIQUES

Deep learning has revolutionized medical image analysis by enabling end-to-end learning without the need for manual feature extraction [8].

### 4.1 Convolutional Neural Networks (CNNs)

CNNs [9], [10] are the backbone of modern image segmentation. Models like U-Net and Fully Convolutional Networks (FCNs) have shown exceptional performance in segmenting AMD-related features.

- **U-Net:** U-Net is a widely used architecture for biomedical image segmentation, featuring an encoder-decoder structure with skip connections. It effectively segments drusen and geographic atrophy with high accuracy.
- **FCNs:** Fully Convolutional Networks adapt standard CNNs for pixel-wise prediction, making them suitable for segmenting fine structures in fundus images.

CNNs are a highly effective DL technique for AMD segmentation from fundus images. CNNs automatically learn hierarchical features from the raw image data, eliminating the need for manual feature extraction. The process begins by feeding the fundus image into the network, where multiple convolutional layers capture local patterns such as textures, edges, and shapes associated with AMD, such as drusen or retinal abnormalities. Pooling layers help reduce spatial dimensions while preserving important features, enabling the network to focus on relevant regions. The fully connected layers at the end of the network perform pixel-wise classification, distinguishing between normal and AMD-affected regions. CNNs can be trained on large datasets of labeled fundus images to optimize the model's accuracy. Once trained, the CNN model can be used to segment AMD regions in new fundus images. Post-processing techniques, like conditional random fields, can be applied to refine boundaries. CNNs excel in handling complex image data, providing high accuracy in segmenting AMD features, which aids in diagnosis and monitoring disease progression.

### 4.2 Transfer Learning (TL)

Transfer Learning [11] leverages pre-trained models on large datasets to improve segmentation performance on AMD images. This approach is particularly useful when annotated data is scarce.

TL is a technique that leverages pre-trained models to improve AMD segmentation from fundus images [12]. Instead of training a deep learning model from scratch, a pre-trained model, typically trained on large datasets like ImageNet, is fine-tuned for the specific task of AMD segmentation. The model's lower layers, which capture general features like edges and textures, are retained, while the higher layers are adapted to recognize AMD-specific features such as drusen or macular changes. Fine-tuning allows the model to learn from the relatively smaller dataset of fundus images while benefiting from the knowledge gained from the large-scale dataset. TL significantly reduces the time and computational resources required for training and helps achieve high accuracy even with limited annotated data. Once fine-tuned, the model is capable of segmenting AMD regions in new fundus images, providing a robust solution for early detection and monitoring of the disease. Post-processing techniques may further refine the segmented regions, enhancing the model's performance.

### 4.3 Recurrent Neural Networks (RNNs)

RNNs, particularly Long Short-Term Memory (LSTM) networks, have been explored for sequential analysis of fundus images. They can capture temporal changes in AMD progression but are less common due to the static nature of most fundus datasets.

RNNs [13] are typically used for sequence data but can also be applied to AMD segmentation in fundus images, especially when analyzing temporal or spatial relationships in image patches. In the context of AMD segmentation, RNNs can capture long-range dependencies between pixels, which is useful for identifying patterns in the distribution of AMD features such as drusen or macular degeneration. For fundus images, a variant like LSTM networks can be used, which helps mitigate the vanishing gradient problem and allows the model to retain information over long distances within the image. By processing sequential data of image patches or regions, RNNs can better capture contextual relationships between neighboring areas, improving segmentation accuracy. These networks can be integrated with CNNs in a hybrid architecture, where CNNs extract spatial features, and RNNs model the sequential dependencies between those features. Once trained, the RNN-based model can segment AMD regions in new images, helping to detect and monitor the progression of the disease. Post-processing, such as morphological operations, may be applied to refine the segmentation results. RNNs are particularly useful in improving segmentation when there are complex, large-scale patterns in the images that need to be captured.



## 5. CHALLENGES, LIMITATIONS AND FUTURE DIRECTIONS

Despite significant advancements, several challenges remain in AMD segmentation:

- **Data Scarcity:** Annotated datasets are limited, hindering the development of robust models.
  - **Variability in Imaging Conditions:** Variations in lighting, image quality, and patient-specific factors complicate segmentation.
  - **Generalizability:** Models trained on specific datasets may not generalize well to different clinical settings. Future research should focus on addressing the limitations and challenges in AMD segmentation. Promising directions include:
    - **Semi-supervised and Unsupervised Learning:** To leverage unlabeled data and reduce the dependency on large annotated datasets.
    - **Multi-modal Imaging:** Combining fundus images with other imaging modalities like OCT to improve segmentation accuracy.
    - **Explainable AI:** Developing interpretable models to enhance clinician trust and understanding of automated segmentation results.

## 6. CONCLUSION

AMD presents a significant challenge for the elderly, causing progressive vision loss and severely impacting quality of life. Early and accurate detection of AMD is critical for effective management, and fundus imaging plays a vital role in identifying key features such as drusen and geographic atrophy. While traditional image processing techniques such as thresholding, edge detection, region growing, and morphological operations have contributed to AMD segmentation, DL approaches, particularly CNNs and TL, have revolutionized the field by providing more automated, efficient, and precise segmentation results.

DL methods, such as U-Net and FCNs, have proven particularly successful in accurately identifying AMD features from fundus images, minimizing the need for manual feature extraction and offering promising results in clinical applications. Moreover, the use of machine learning models like SVMs and RF has enhanced classification accuracy by leveraging large feature sets. However, these methods still face challenges such as data scarcity, variability in image quality, and the generalization of models across different clinical settings.

Despite these advancements, there are notable challenges in the field, including the limited availability of annotated datasets, variations in imaging conditions, and the complexity of segmenting heterogeneous regions. Future research should address these limitations by exploring semi-supervised and unsupervised learning techniques, as well as integrating multi-modal imaging methods like OCT for improved segmentation. Additionally, incorporating explainable AI models will be crucial to gaining clinician trust and providing more transparent results.

In conclusion, the future of AMD segmentation lies in overcoming these challenges through the integration of advanced DL models, better data utilization, and the continuous development of innovative, multimodal imaging approaches. As these techniques evolve, they hold the potential to significantly enhance early detection, monitoring, and management of AMD, ultimately improving patient outcomes.

## 7. REFERENCES

- [1] Syed A.M., Akram M.U., Akram T., Muzammal M., Khalid S., and Khan M.A., 2018, 'Fundus images-based detection and grading of macular edema using robust macula localization', IEEE access, vol. 6, pp. 58784-58793.
- [2] Li X., Hu X., Yu L., Zhu L., Fu C.W., and Heng P.A., 2020, 'CANet: Cross-disease Attention Network for joint diabetic retinopathy and diabetic macular edema grading', IEEE transactions on medical imaging, vol. 39, issue 5, pp. 1483-1493.
- [3] Zar K.T., Hlaing T.T., and Maung S.S., 2020, 'An enhancement of underwater images using CLAHE and fusion', International research journal of modernization in engineering technology and science, vol. 2, issue 10, pp. 906-918.
- [4] Manju R.A., Koshy G., and Simon P., 2019, 'Improved method for enhancing dark images based on CLAHE and morphological reconstruction', Procedia computer science, vol. 165, pp. 391-398.
- [5] Floriano A.G., Santiago A.F., Nieto O.C., and Marquez C.Y., 2019, 'A machine learning approach to medical image classification: Detecting age-related macular degeneration in fundus images', Computers & electrical engineering, vol. 75, pp. 218-229.

- [6] El-Khalek A.A.A., Balaha H.M., Alghamdi N.S., Ghazal M., Khalil A.T., Abo-Elsoud M.E.A., and El-Baz A., 2024, 'A concentrated machine learning-based classification system for Age-related Macular Degeneration (AMD) diagnosis using fundus images', Scientific reports, vol.14, issue 1, pp. 1-20.
- [7] Wang X., Wang S., Zhu Y. and Meng X., 2012, 'Image segmentation based on Support Vector Machine', Proceedings of 2012 2nd International Conference on Computer Science and Network Technology, Changchun, China, pp. 202-206.
- [8] Xu K., Huang S., Yang Z., Zhang Y., Fang Y., Zheng G., Lin B., Zhou M., and Sun J., 2023, 'Automatic detection and differential diagnosis of age-related macular degeneration from color fundus photographs using deep learning with hierarchical vision transformer', Computers in biology and medicine, vol. 167, pp. 1-11.
- [9] Mahmud B.U. and Hong G.Y., 2022, 'Semantic Image Segmentation using CNN (Convolutional Neural Network) based Technique', IEEE world conference on applied Intelligence and Computing (AIC), Sonbhadra, India, pp. 210-214.
- [10] Wang W., Li X., Xu Z., Yu W., Zhao J., Ding D., and Chen Y., 2011, 'Learning two-stream CNN for multi-modal age-related macular degeneration categorization', IEEE journal of biomedical and health informatics, vol. 26, issue 8, pp. 4111-4122.
- [11] Karimi D., Warfield S.K., and Gholipour A., 2021, 'Transfer learning in medical image segmentation: New insights from analysis of the dynamics of model parameters and learned representations, Artificial intelligence in medicine, vol. 116, Article no. 102078.
- [12] Kim H.E., Linan A.C., Santhanam N., Jannesari M., Maros M.E., and Ganslandt T., 2022, 'Transfer learning for medical image classification: a literature review', BMC medical imaging, vol. 22, pp. 1-13.
- [13] Wang J., Tang Y., Xiao Y., Zhou J.T., Fang Z. and Yang F., 2024, 'GREnet: Gradually REcurrent Network With Curriculum Learning for 2-D Medical Image Segmentation', IEEE Transactions on Neural Networks and Learning Systems, vol. 35, issue 7, pp. 10018-10032.