

## EVALUATION OF NEPHROPROTECTIVE ACTIVITY OF EURYCOMA LONGIFOLIA EXTRACT IN EXPERIMENTAL ANIMAL MODEL

Dr Rangu Nirmala<sup>1</sup>, Shafiya Begum<sup>2</sup>

<sup>1</sup>Associate Professor, Department of Pharmacology, Surabhi dayakar Rao college of Pharmacy, Gajwel, Siddipet, Telangana 502312, India

<sup>2</sup>Student, Surabhi dayakar Rao college of Pharmacy, Gajwel, Siddipet, Telangana 502312, India.

DOI: <https://www.doi.org/10.58257/IJPREMS36003>

### ABSTRACT

**Objective:** -To investigate the Nephroprotective activity of ethanol extract of Eurycoma Longifolia on Gentamicin induced Nephrotoxicity in male Wistar rats.

**Material & method:** - In this model of Nephrotoxicity, 30 adult male wistar rats (150-200gms) were evenly divided into 5 groups. Group-1 and Group-2 served as untreated and model controls respectively, while Group-3, 4 and 5 were the treatments groups which were simultaneously treated with standard, 200 and 400 mg/kg extract respectively, after each dose Gentamicin (80 mg/kg, i.p.) for 10 day. On 11 th day, blood samples for biochemical parameters, while the rats kidneys for histology were obtained under inhaled diether anaesthesia.

**Results:** - Gentamicin treatment caused Nephrotoxicity as evidenced by marked elevation in blood urea, uric acid and Creatinine. Co-administration of extract with Eurycoma Longifolia decreased rise in blood urea, uric acid and Creatinine. Apart from these, histopathological changes also showed the protective nature of extract against Gentamicin induced necrotic damage of renal tissues.

**Conclusion:** - It was observed that the ethanol extract of conferred nephroprotective activity by histopathological and biochemical observation against Gentamicin induced Nephrotoxicity in rats. In the near future could constitute a lead to discovery of a novel drug for treatment of drug induced Nephrotoxicity.

**Keywords:** Nephrotoxicity. Eurycoma Longifolia, Gentamicin.

## 1. INTRODUCTION

Nephroprotective agents are material that has potential to minimize the effects of nephrotoxic agents. Medicinal plants have curative properties due to the presence of various complex chemical substances. Ethnomedicinal plants from the traditional system of medicine viz Ayurveda and Unani, which are acclaimed by the Ayurvedic and Unani physicians to have nephroprotective properties and commonly used to treat various renal disorders, have been extensively investigated for their significant nephroprotective effects.

Eurycoma longifolia (EL) is a small Asian tree in the genus Eurycoma, commonly known as Tongkat ali or Long Jack, the roots of which are often called "Malaysian ginseng". It is used in the treatment of malaria, cancer and ulcers and for male sexual dysfunction and has been commonly prescribed in traditional medicine as a febrifuge and a remedy for dysentery, glandular swelling and fever. It is popular as a singly or an essential component for the treatment of fevers, aches and sexual insufficiency as well as health supplements. EL has also been reported to have antioxidative properties due to its high concentration of superoxide dismutase

## 2. MATERIALS AND METHODS

### 2.1 Collection of plant material:

Eurycoma Longifolia used for the present studies was collected Local market. The bark was cut into small pieces and shade dried. The dried material was then pulverized separately into coarse powder by a mechanical grinder. The resulting powder was then used for extraction. The powdered drug was dried and packed well in Soxhlet apparatus and extracted with 1500 ml of ethanol for seven cycles. The extract was concentrated and dried using Rotary flash evaporator. It was kept in desiccators' until used.

### 2.2 Experimental Animals

Swiss Albino rats adult of either sex were obtained from Local vendor. The rats were divided randomly into 5 groups of 6 rats each for each model. Each rat that weighed between 180-200 gm was housed separately (Four rats per cage). The animals were left for 48 hrs to acclimatize to the animal room conditions. They were maintained in standard laboratory conditions of temperature 22±2°C, humidity, 12 hours light and dark cycles fed with standard pellet diet (Hindustan lever, Bangalore) and adequate tap water.

### 2.3. Acute Toxicity Studies:

Animals will be fasted prior to dosing, food but not water should be withheld overnight. Following the period of fasting, the animals will be weighed and the test substance will be administered. After the substance is administered, food may be withheld for a further 3-4 hrs. As a dose is administered in fractions over a period, it may be necessary to provide the animals with food and water depending on the length of the period.

Three animals will be used for each step. The dose level used as the starting dose will be selected from one of the four fixed levels, 5, 50, 300 and 2000 mg/kg body weight. The starting dose level should be that which is most likely to produce mortality in some of the dose animals. The animals will be observed for behavioral changes for 4 hrs and 48 hrs for mortality.

### 2.4. In vivo model:

#### Nephroprotective studies

Effect of Eurycoma Longifolia on Gentamicin-induced Nephrotoxicity

Experimental design: Rats will be divided into five groups, each group consisting of six animals.

Group 1: Control with normal saline (5 ml/Kg)

Group 2: Gentamicin (80 mg/kg/body weight, i.p.), daily for 10 days

Group 3: Ethanol extract of Eurycoma Longifolia (200 mg/kg/body weight, p.o) and simultaneously administered Gentamicin (80 mg/kg/body weight, i.p.), daily for 10 days.

Group 4: Ethanol extract of Eurycoma Longifolia (400mg/kg/body Weight, p.o.) and simultaneously administered Gentamicin (80 mg/kg/body weight, i.p.), daily for 10 days.

Group 5: Silymarin (25mg/kg/body Weight, p.o.) and simultaneously administered Gentamicin (80 mg/kg/body weight, i.p.), daily for 10 days.

At the end of experimental period, all the animals will be sacrificed under diethyl ether anesthesia. Blood samples will be collected, allowed to clot. Serum was separated by centrifuging at 2500 rpm for 15 min and analyzed for various biochemical parameters.

#### Assessment of kidney function

Biochemical parameters i.e., Estimation of Blood urea, Creatinine and uric acid were analyzed according to the reported methods. The kidney was removed, weighed and morphological changes were observed. A portion of kidney was fixed in 10% formalin for histopathological studies.

### 2.5. Statistical analysis of data:

Results were expressed as mean  $\pm$  S.E.M. The statistical difference between the groups in the term of the mean rate of wound healing was calculated in terms of ANOVA mean  $\pm$  S.E.M. The difference was considered significant if  $P < 0.05$ .

## 3. RESULTS AND DISCUSSION

In Gentamicin treated group of animals the concentration of serum urea and Creatinine were considerably increased than the normal animals (group 1) which indicates severe Nephrotoxicity. Treating (Group 4 & 5) with ethanol extract of showed significant decrease ( $p < 0.001$ ) in concentration of serum urea and Creatinine compared to Gentamicin treated group 2. Nevertheless the concentration of uric acid not so much considerably increased in the Gentamicin treated groups (group 2) than control group (group1). Treatment with ethanol extract of significantly ( $p < 0.05$ ) decreases the uric acid levels in group 4 & 5 ( $p < 0.01$ ) compared to Gentamicin treated group (group 2).

**Table 1.** Effect of 80 mg/kg/day intraperitoneal Gentamicin and Eurycoma Longifolia oral on serum Creatinine; blood urea and serum uric acid in treated rats for 10 days

Group	Drug treatment	Serum Creatinine (mg/dl)	Blood urea (mg/dl)	Uric acid (mg/dl)
1	5 ml/kg, i.p, NS	0.675 $\pm$ 0.04251	20.569 $\pm$ 2.871	6.0256 $\pm$ 0.3651
2	80 mg/kg,i.p, Gentamicin	2.145 $\pm$ 0.03701	115.81 $\pm$ 2.531	6.462 $\pm$ 1.152
3	80 mg/kg,i.p, Gentamicin+200 mg/kg	0.8962 $\pm$ 0.0417	53.145 $\pm$ 2.264	4.148 $\pm$ 0.1381

4	80 mg/kg,i.p,Gentamicin+Eurycoma Longifolia +400 mg/kg	0.7212±0.05146	48.432±2.102	3.5102±0.2134
5	80mg/kg,i.p,Gentamicin+Silymarin 25 mg/kg	0.7012±0.02451	46.761±3.102	3.1230±0.1351

#### Kidney weight:

In Gentamicin treated group of animals weight of kidneys were considerably increased compared to normal animals (group1) and treating (group 4 & 5) with ethanolic extract showed significant decrease ( $p<0.001$ ) in kidney weight.

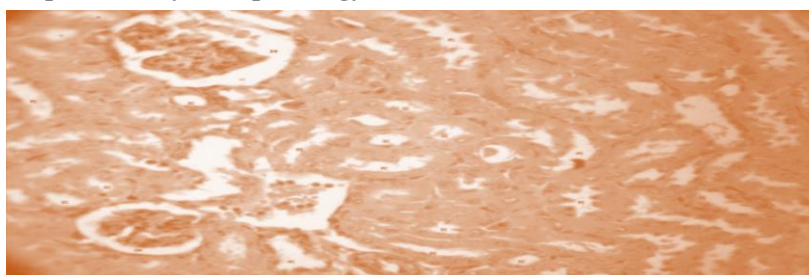
**Table 2:** Effect of 80 mg/kg/day intraperitoneal Gentamicin and Eurycoma Longifolia oral on kidney weight in treated rats for 10 days

Group	Drug treatment	Kidney weight (gm)
1	10 ml/kg, i.p, NS	0.521±0.0159
2	80 mg/kg,i.p, Gentamicin	0.710±0.0201
3	80mg/kg,i.p,Gentamicin+200 mg/kg	0.636±0.0821
4	80mg/kg,i.p, Gentamicin+Eurycoma Longifolia +400 mg/kg	0.521±0.009
5	80mg/kg,i.p,Gentamicin+Silymarin mg/kg	0.501±0.0078


**Table 3:** Effect of 80 mg/kg/day intraperitoneal Gentamicin and Eurycoma Longifolia oral on SGOT, SGPT, ALP in treated rats for 10 days

Group	Drug treatment	SGPT levels ( U/L )	SGOT levels ( U/L )	ALP levels ( U/L )
A	10 ml/kg, i.p, NS	43.68±2.14	42.01±0.51	32.41±2.60
B	80 mg/kg,i.p, Gentamicin	122.02±3.25	135.21±1.21	91.01±2.11
C	80 mg/kg,i.p, Gentamicin+200 mg/kg	85.14±0.54	92.45±1.76	72.70±2.08
D	80mg/kg,i.p,Gentamicin+Eurycoma Longifolia +400 mg/kg	62.21±1.19	53.11±2.29	50.11±3.03
E	80 mg/kg,i.p, Gentamicin+Silymarin mg/kg	44.401±2.03	46.20±3.46	43.12±0.19

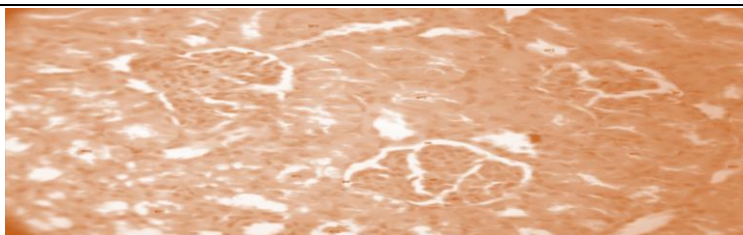
#### Gentamicin induced Nephrotoxicity Histopathology



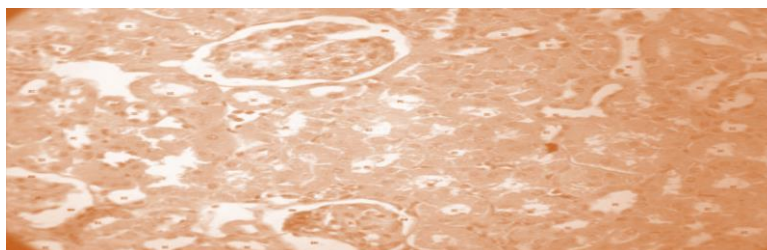
**FIG 1:** A sectional representation of normal rat kidney showing normal glomeruli with an intact Bowman's capsule, proximal convoluted and distal convoluted tubules



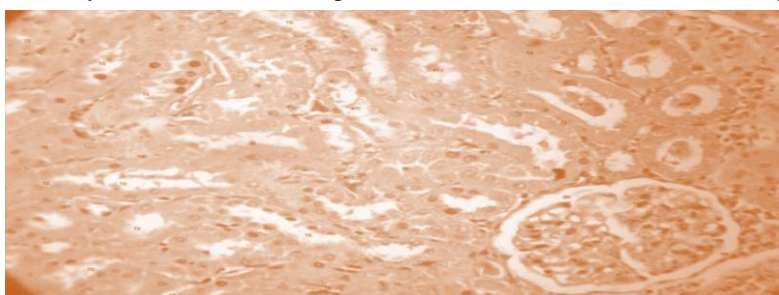
**FIG 2:** A representative section Gentamicin-intoxicated rat kidney showing severe hydropic glomerular degeneration obliterated proximal convoluted tubular lumen and obliterated distal convoluted tubular lumen. The tubular lumens were completely obliterated and filled with fluid and casts



**FIG3:** A sectional representation of 200 mg/kg/day, Gentamicin–intoxicated rat kidney showing mesangial proliferation with thinning out of the Bowman's capsule. There is mild tubular cast deposition interposed with normal proximal convoluted tubule and distal convoluted tubule



**FIG 4:** A sectional representation of 400 mg/kg/day Gentamicin–intoxicated rat kidney showing normal glomeruli encapsulated by normal Bowman's capsule. There is no obvious tubular cast deposition



**FIG 5** A sectional representation of 25 mg/kg/day Gentamicin–intoxicated rat kidney showing moderate tubular degeneration with normal glomeruli and Bowman's capsule .

#### 4. CONCLUSION

The extract of *Eurycoma Longifolia* treated group animals were found to reduce such changes in kidney histology induced by Gentamicin and acetaminophen, indicating nephroprotection. Further documented reports reveal that, plant material containing phenols, flavonoids, alkaloids and saponins offers organ protection by virtue of their free radical scavenging activity. The extract under study upon phytochemical analysis showed the presence of a for mentioned Phytoconstituents. Hence, the role of these Phytoconstituents as free radical scavengers and consequent nephroprotection cannot be ruled out.

Gentamicin induced Nephrotoxicity was significantly prevented by concomitant with ethanolic extract of *Eurycoma Longifolia*. Reduction in elevated biochemical parameter levels like serum SGPT, SGOT, ALP after treatment with ethanolic extract of *Eurycoma Longifolia* confirmed the Nephro-protective effect of extract under study.

#### 5. REFERENCES

- [1] T Abbas K, Rizwani GH, Zahid H, Qadir MI. Evaluation of nephroprotective activity of *Musa paradisiaca* L. in gentamicin-induced nephrotoxicity. *Pak J Pharm Sci.* 2017 May;30(3), pp881-890.
- [2] M.Aparna rama laxmi devi, M.Yaso Deepika, B.Nagaraju3 , K.Prasad. Evaluation of Nephroprotective Activity of Ethanolic Extract of *Annona reticulata* in Gentamicin and Cisplatin Induced Nephrotoxicity in Rats. *J. Pharm. Sci. & Res.* Vol. 8(9), 2016, pp995-1007.
- [3] Nisha Sonkar, Aditya Ganeshpurkar, Priyanka Yadav, Shagun Dubey, Divya Bansal, and Nazneen Dubey. An experimetal evaluation of nephroprotective potential of *Butea monosperma* extract in albino rats. *Indian J Pharmacol.* 2014 Jan-Feb; 46(1):pp 109–112.
- [4] Yadav YC, Srivastava DN. Nephroprotective and curative effects of *Ficus religiosa* latex extract against cisplatin-induced acute renal failure. *Pharm Biol.* 2013 Nov;51(11), pp1480-5.
- [5] Hussain T, Gupta RK, Sweetey K, Eswaran B, Vijayakumar M, Rao CV. Nephroprotective activity of *Solanum xanthocarpum* fruit extract against gentamicin-induced nephrotoxicity and renal dysfunction in experimental rodents. *Asian Pac J Trop Med.* 2012 Sep;5(9), pp686-91.